

The Protective Effect of Nabk Honey Against Pathological Effects of Penicillin and Streptomycin on Histological Structure and Functions of Guinea pigs Liver

Mohammed S.A.Al-Awar^a, Elham A. S. AL- Shaibani^b, Elias M.A.Salih^c, Mohammed A.Y.Al-Eryani^a

^aDepartment of Biology, Faculty of Education, University of Amran, Yemen.

^bDepartment of Biology, Faculty of Science, University of Sana'a, Yemen.

^cDepartment of Biology, Faculty of Education, University of Aden, Yemen.

ARTICLE INFO

Article history:

Received on: 19/03/2013

Revised on: 12/04/2013

Accepted on: 24/04/2013

Available online: 12/05/2013

Key words:

Hypoprotective, Honey, Penicillin, Streptomycin, Histopathologic and Biological Study.

ABSTRACT

This study was designed to determine the protective effect of nabk honey as antioxidant against pathological effects of penicillin and streptomycin histological structure and functions of guinea pigs liver . A total of sixty adult male guinea pigs weighting 800-900g were divided into six groups of ten guinea pigs each, and the experiment lasted 30 days. Animals in group I served as control, animals in group 2 were administrated orally with nabk honey 600 mg/kg, animals in group 3 were intraperitoneally (i.p.) injected with penicillin 50000 IU/kg b.w, animals in group 4 in addition penicillin were orally administrated with nabk honey 600 mg/kg, animals in group 5 were (i.p.) injected with streptomycin 50 mg/kg, and animals in group 6 in addition streptomycin were orally administrated with nabk honey 600 mg/kg. The result showed a significant increase in AST, ALT & ALP levels, and a significant decrease in the levels of total protein and albumin, and addition to histopathological changes in penicillin and streptomycin treated guinea pigs when compared to the control guinea pig. The results of honey administration decreased these histopathological changes, the structure of liver and hepatocytes appearance was more or less similar to control group as well its function. The present results indicate that honey may play an important role as cytoprotective and pave the way for further studies on the possible use of honey.

INTRODUCTION

Bacterial infections are one of the leading infectious diseases confronting public health and the antibacterial therapy remains relevant in treatment and control of such infections especially in developing countries (Barry, 1999). The increase in the rate of resistance of microorganisms to monotherapy is increasingly alarming and has necessitated use of combination therapy in treatment of some infectious diseases (Brunton *et al*, 2008). For instance, penicillin G or amoxicillin were the mainstay therapy for pneumococcal infections, however, bacterial resistance to penicillins, cephalosporins and non-beta lactam antibiotics have escalated in the last two decades (Jones and Pfaller, 1998; Barry, 1999). Therefore, complete cure may not be achieved with penicillins or cephalosporins monotherapies when use against *Streptococcus pneumoniae* (Friedland, 1994).

This and many other cases have necessitated the combination of two or more different antibiotics to obtain improved effects in the treatment of infections and many have proved efficacious. In an experiment, penicillin-streptomycin gave total cure in mice infected with *Streptococcus pneumoniae* (Udeani and Kalu, 2003). Penicillin and streptomycin are narrow spectrum drugs with effects usually on Gram positive and negative organisms, respectively (Rossi, 2004; Bishop, 2006) resulting in potential increase in toxic effects or reduced efficacy (Hansten, 1998; Brunton *et al*, 2008). Liver being the largest organ in the body and functionally responsible for detoxification of drugs and xenobiotics (Ganong, 2006), and usually suffers most of these potential toxic effects. The damage in liver function usually manifesting as altered activities of liver enzymes such as liver alkaline phosphatase, transaminases and moreover sometimes altered total serum protein (Bass, 2003). Acute liver injury has been described as the leading cause of drug withdrawal based on safety grounds (Bakke *et al*, 1995).

* Corresponding Author

*E-mail: momed.sades@gmail.com

Phone number: 00967-771227420.

Honey is a natural product of honey bees formed from nectar collected from blossoms. It has been reported that honey contains moisture and carbohydrates including sugars such as fructose and glucose (Mohamed, 2005).

It also contains enzymes such as catalase and glutathione reductase, minerals such as iron and zinc, vitamins such as vitamins A and E as well as phenolic compounds and organic acids (Al-Waili *et al.*, 2003; Mato *et al.*, 2003; Michalkiewicz *et al.*, 2008).

Scientific studies have shown that honey possesses some biological properties such as antimicrobial (Tan *et al.*, 2009), anti-inflammatory (Bilsel *et al.*, 2002) and antioxidant (Perez *et al.*, 2006). Oxidative stress has been implicated in the development of many chronic diseases (Halliwell *et al.*, 1992).

The therapeutic role of honey in the treatment of various ailments has been receiving considerable attention recently, and its therapeutic value has been partly attributed to its antioxidant properties (Johnston *et al.*, 2005; Beretta *et al.*, 2005; Elizabeth *et al.*, 2006). Many studies of the different indicate to protective effects of honey against many alteration caused by organophosphate insecticides and some medicines that induced hepatotoxicity (Mohamed, 2005 ; Abdel-Moneim and Ghafeer, 2007; Ismael and Ashour, 2007; Khadr *et al.*, 2007; El-Khayat 2009; Eminatedoki *et al.*, 2010).

We have not found in the previous literatures any study on protective effect of honey against penicillin and streptomycin-induced hepatotoxicity.

The goal of this study is to investigate determine the protective effect of nabk honey as antioxidant against pathological effects of penicillin and streptomycin histological structure and functions of guinea pigs liver.

MATERIALS AND METHODS

Materials

Nabk honey (local Product Yemen-Haiiah-Mabian), Penicillin and Streptomycin were purchased powder from (Ave Group-USA-Colombia-Mexico), All chemicals were of analytical reagent grade and chemicals required for all biochemical assays were obtained from Sigma-Aldrich Chemicals Co. (St.louis, Mo, USA).

Experimental Animals

60 healthy adult male guinea pigs (weighing 800 – 900 g), were obtained from the animal rearing zoo- Sana'a- Yemen. Animals were housed in the animal house - Department of Biology- Faculty of Science- Sana'a university, under standard lighting and relative humidity conditions in a temperaturecontrolled room ($25 \pm 2^\circ\text{C}$) and relative humidity of $25 \pm 5\%$). Animals were allowed to acclimatize to the laboratory environment for 30 days, and the were given (Fresh grass hay, Alfalfais, Legume (HCDGP, 2007, GPCS, 2007 and ILAR 1995) and tap water *ad libitum*, Subsequently the animals were randomly divided to 6 groups , 5 animals in group (2) and 10 animals in groups (1,3-6). Treatments were carried out over a period of 30 days. Hence, our Treatments groups were as follows:

Group1 (C): Control (5 ml/kg saline solution orally administrated).

Group2 (H): Honey (60 mg/kg orally administrated). (Gharzouli, 2001; Abas, 2010).

Group3 (P): Penicillin (5000IU/kg intraperitoneal injection). (Harold, 1998; Akande *et al.*, 2012).

Group4 (P+H): Penicillin + Honey (50000 IU/kg intraperitoneal injection + 1000UI/kg orally administrated).

Group5 (S): Streptomycin (50 mg/kg intraperitoneal injection). (Brahin, 2008; Akande *et al.*, 2012).

Group6 (S+H): Streptomycin + Honey (600mg/kg intraperitoneal injection + 1000UI/kg orally administrated).

After 30 day of treatment, guinea pigs in all groups were fasted overnight for 12h, and sacrificed and dissected under ether anaesthesia, the blood was immediately collected and centrifuged, and serum was discarded and kept at $- 21^\circ\text{C}$ for the biochemical tests, and the liver tissues were removed as small pieces.

Estimation of liver function

Alanine- aminotransferase (ALT) and Asparatate- aminotransferase (AST) Assay

The estimation was carried out according to the method originally developed by Reitman and Frankel (1975).

Alkaline phosphatase Assay

ALP was determined using a colorimetric method as described by Kind and King (1954).

Total Protein Assay

The total protein was determined by Biuret method explained by Tietz (1976).

Albumin Assay

Serum albumin was determined according to the method of Doumas *et al.*, (1971).

Histological Studies

The liver of each guinea pig were removed. Small pieces of liver were taken, then fixed by using a 10% neutral formalin. The fixed tissues were dehydrated in series of alcohol concentrations 70%, 80%,90% and 100%. The dehydrated tissues were then cleared by using xylene as clearing agents. Then the cleared tissues were embedded in paraffin wax at 60°C . Blocks were cut at 5mm thick and stained with hematoxylin and eosin (Humason, 1979).

Statistical analysis

The statistical analysis was performed by SPSS; continuous data are expressed as mean \pm S.E. Data were compared using one – way ANOVA. P value <0.01 was considered to be statistically significant. post hoc analysis of grope differences was performed by LSD test. The treated groups were compared both with each other and with untreated control groups.

RESULTS

Biochemical results

Results in table 1 show that the (i.p) administration of Penicillin in a single dose 50000 IU/kg b.w. per day period of 30 day (Group3). resulted in high significant $P<0.01$ increase in the level of AST, ALT and ALP, as compared to control (Group1), Penicillin i.p. administration resulted also in high significant $P<0.01$ decrease in the level of albumin and total protein, as compared to the control (Group1).

The administration of honey in a single dose 600 ml/kg b.w. per day period of 30 day (Group2). Resulted in non significant $P<0.01$ change in the level of AST, ALT, ALP, albumin and total protein, as compared to the control (Group1). Results showed that honey significantly ($P<0.01$) reduced the toxicity of penicillin, where administration of Nabk honey in dose 600 mg/kg b.w. per day (Group4) beside Penicillin, resulted in non significant $P<0.01$ change in the level of AST, ALT, ALP, albumin and total protein, as compared to the control. Results in table 2 show that the (i.p) administration of Streptomycin in a single dose 50 mg/kg b.w. per day period of 30 day . resulted in high significant $P<0.01$ increase in the level of AST, ALT and ALP, as compared to control, Streptomycin i.p. administration resulted also in high significant $P<0.01$ decrease in the level of albumin and total protein, as compared to the control.

Results also showed that honey significantly ($P<0.01$) reduced the toxicity of Streptomycin, where administration of Nabk honey in dose 600 mg/kg b.w. per day (Group6) beside Streptomycin, resulted in non significant $P<0.01$ change in the level of AST, ALT, ALP, albumin and total protein, as compared to the control.

Histological results

The control livers show normal lobular architecture with central vein and radiating cords of hepatocytes, separated by blood sinusoids. Hepatocytes are large and polyhedral in shape with slightly acidophilic granular cytoplasm. They have large, rounded, vesicular nuclei with prominent nucleoli (Fig. 1,2).

The liver cells of group 3,5 animals showed obvious histological changes, in the form of distortion in the hepatic organization, dilatation and congestion of the blood sinusoids and central vein, infeltration, heamorrhage, congestion, inflammation, metaplasia, hyperplasia, hypertrophy, necrosis, vasodilatation, thickning in the central vein, Some hepatocytes showed signs of degeneration in the form of hypertrophy with highly vacuolated cytoplasm and deeply stained nuclei. Other hepatocytes exhibited hyalinized cytoplasm with pale nuclei and prominent nucleoli (Fig.3,5). The liver cells of group 4,6 appeared more or less similar to those of the control apart from few hepatocytes appeared with vacuolated cytoplasm and pyknotic nuclei (Fig.3,5).

Table. 1: Statistical Analysis of Result of Liver Function Tests after 30 days of Penicillin and Nabk honey administration in dose 50000 IU/kg and 600 mg/kg respectively.

Parameter Groups	AST U/L		ALT U/L		ALP U/L		Total Protein g/dl		Albumin g/dl	
	M±SD	Change	M±SD	Change	M±SD	Change	M±SD	Change	M±SD	Change
Control	21.95±1.7	-----	27.41±1.8	-----	52.91±2.2	-----	7.52±0.28	-----	3.78±0.15	-----
Honey	20.71±1.9 ^a	5.6%	27.33±1.8 ^a	0.3%	54.28±2.1 ^a	2.3%	7.69±0.21 ^a	2.3%	3.88±0.22 ^a	2.6%
Penicillin	46.88±4.9 ^C	113.6%	63.06±5.6 ^C	130.1%	78.06±4.3 ^C	47.5%	6.03±0.45 ^C	19.8%	2.96±0.18 ^C	21.7%
P + honey	24.58±2.5 ^a	12%	30.71±2.3 ^b	12%	55.33±2.5 ^a	4.6%	7.38±0.42 ^a	1.9%	3.68±0.12 ^a	4.8%
ANOVA	139.88		238.01		148.58		37.70		61.01	
F-Value	P<0.01		p<0.01		p<0.01		p<0.01		p<0.01	
(DF-34)	Sig		Sig		Sig		Sig		Sig	

The values are given as Mean±Standard Deviation (M±SD), degrees of freedom (df), (in each group).^aNon significance,-^bLow significance,-^CHigh significance at ($P<0.01$) vs. control.

Table. 2: Statistical Analysis of Result of Liver Function Tests after 30 days of Streptomycin and Nabk honey administration in dose 50 mg/kg and 600 mg/kg respectively.

Parameter Groups	AST U/L		ALT U/L		ALP U/L		Total Protein g/dl		Albumin g/dl	
	M±SD	Change	M±SD	Change	M±SD	Change	M±SD	Change	M±SD	Change
Control	21.95±1.7	-----	27.41±1.8	-----	52.91±2.2	-----	7.52±0.28	-----	3.78±0.15	-----
Honey	20.71±1.9 ^a	5.6%	27.33±1.8 ^a	0.3%	54.28±2.1 ^a	2.3%	7.69±0.21 ^a	2.3%	3.88±0.22 ^a	2.6%
Streptomycin	60.35±6.8 ^C	174.9%	79.36±3.5 ^C	189.5%	88.46±3.4 ^C	67.2%	5.44±0.35 ^C	27.7%	2.29±0.12 ^C	39.4%
S + honey	25.12±3.3 ^a	14.4%	33.33±3.8 ^b	21.6%	56.57±3.9 ^a	6.9%	7.28±0.33 ^a	3.2%	3.30±0.14 ^a	12.7%
ANOVA	185.51		258.08		288.01		102.87		208.79	
F-Value	P<0.01		P<0.01		P<0.01		P<0.01		P<0.01	
(DF-34)	Sig		Sig		Sig		Sig		Sig	

The values are given as Mean±Standard Deviation (M±SD), degrees of freedom (df), (in each group).^aNon significance,-^bLow significance,-^CHigh significance at ($P<0.01$) vs. control.

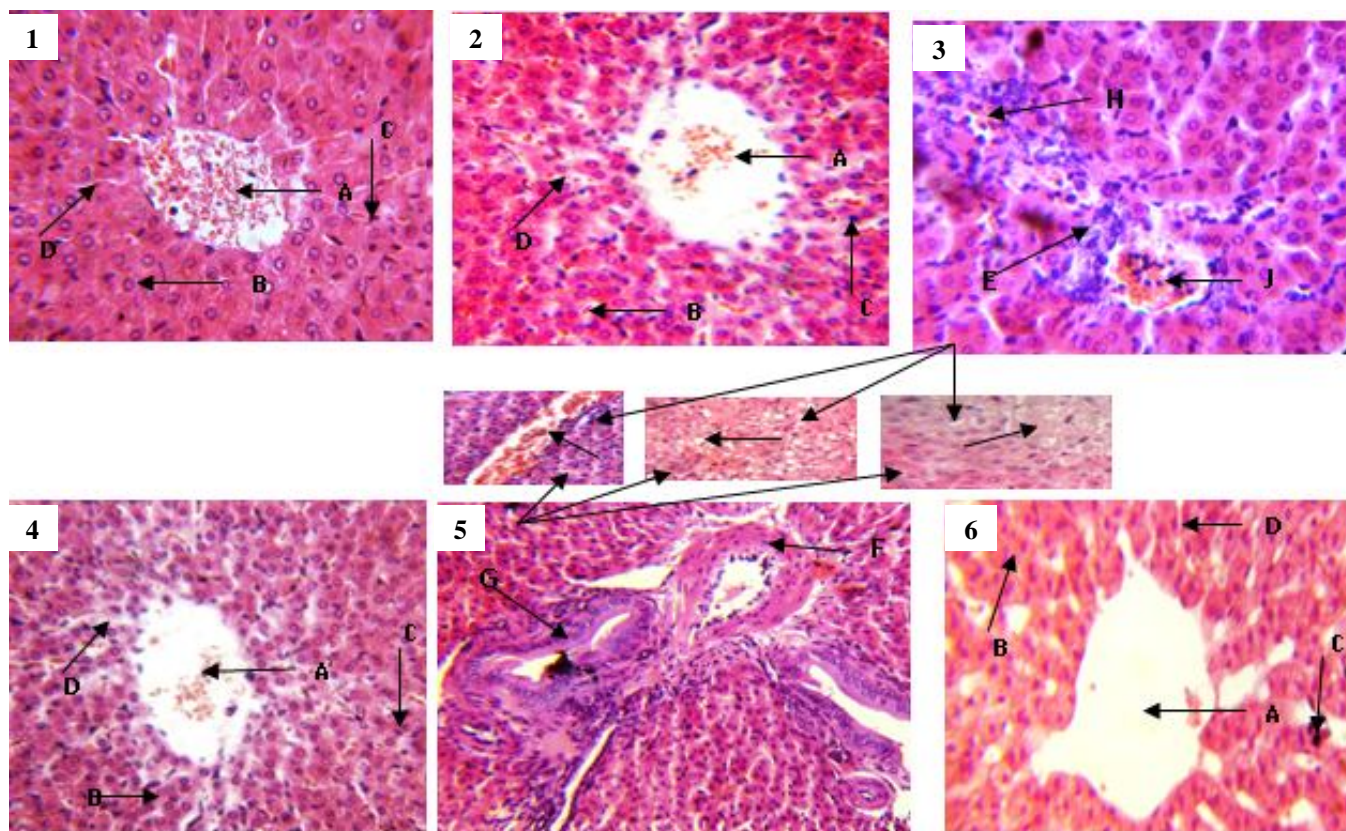


Fig. (1-6): Hepatoprotective effect of Nabk Honey against Penicillin and Streptomycin-Induced Hepatotoxicity in Guinea pig. Liver sections were stained H & E. (1) Control; (2) Nabk honey (600mg/kg b.w); (3) Penicillin- treated animals (50000 IU/kg b.w); (4) Penicillin+nabk honey (50000 IU/kg b.w +600 mg/kg b.w); (5) Streptomycin- treated animals (50 mg/kg b.w); (6) Streptomycin +nabk honey (50mg/kg b.w +600 mg/kg b.w); (A)Central vein; (B) Hepatocytes; (C) Kupver cells; (D) Sinusoids; (E) Infeltration; (F) Thickning in the central vein; (G) Metaplasia; (H) Heamorrhage; (I) Vasodilatation; (J) Congestion; (Q) Hypertrophy; (N) Necrosis; (M) Odema.

DISCUSSION

Liver, a vital organ in vertebrates, performs wide range of functions such as detoxification, plasma protein synthesis and metabolism of drugs among other functions (Ganong, 2006). During these activities, liver could be exposed to toxicity from these agents which may manifest clinically or only as abnormal liver enzymes activities (Lee, 2003). The liver is the most sensitive organ to preoxidative damage because it is rich in oxidizable substances. The increment of the oxidative stress on the cells of the liver and the consequent decrease in the antioxidant ability of the cells result in the occurrence of aggressive cellular damage to the liver cells with destruction of their membranes and the release of the enzymes into the blood stream (Sallie *et al*, 1991). The more severe the liver damage the higher the release of the liver enzymes (Rowland and Tozer, 1989).

In the assessment of liver damage certain biomarkers of hepatotoxicity are measured and one of such biomarkers are enzyme levels such as AST and ALT because liver damage arising from necrosis or membrane damage normally releases the enzymes into circulation; therefore, measurement of these enzymes in serum gives an indication of the health status of the liver. High levels of AST indicate liver damage, as that due to viral hepatitis as well as cardiac infarction and muscle injury. ALT catalyses the conversion of alanine to pyruvate and glutamate, and is released in

a similar manner. It is known that an increase in the enzymatic activity of ALT and AST in the serum directly reflects a major permeability or cell rupture, and thus ALT is more specific to the liver, and is thus a better parameter for detecting liver injury (Wittwer and Bouhmwald, 1986; Pratt and Kaplan, 2000). An increase in AST and ALT, a hepatospecific enzyme that is principally found in the cytoplasm of ginea pig following administration of a hepatotoxin is attributed to the increased release of enzymes from the damaged liver parenchymal cells (Benjamin, 1978; Singh, 1980 ; Hansten, 1998 ; Pratt and Kaplan, 2000; Garba *et al*, 2009). The elevated level of alkaline phosphatase an enzyme produced in the liver, bone and placenta indicates liver injury or bile duct obstruction as a result of penicillin and streptomycin administration. Liver injuries are mostly caused by interference with the metabolic pathways essential for parenchymal cell integrity. They lead to diversion, competitive inhibition or structural distortion of molecules essential for metabolism or to selectively blockade of key metabolic pathways required to maintain the intact hepatocyte. The biochemical and physiological lesions induced by these agents lead to degenerative changes such as steatosis, necrosis or both (Whitby *et al*, 1984 ; Garba *et al*,2006). Oedema in this result denotes excess plasma fluid in the interstitium which normally causes an expansion in the intracellular matrix and a major local

manifestation of acute inflammation in dividing resident of lymphocytes or macrophages (Kumar *et al.*, 2004). Serum AST, ALT is the most sensitive biomarkers used in the diagnosis of liver diseases (Pari and Kumar, 2002). During hepatocellular damage, varieties of enzymes normally located in the cytosol are released into the blood flow. Their quantification in plasma is useful biomarkers of the extent and type of hepatocellular damage (Pari and Murugan, 2004). Serum ALT catalyses the conversion of alanine to pyruvate and glutamate, and is released in a similar manner. Therefore, serum ALT is more specific to the liver, and is thus a better parameter for detecting liver injury (Williamson *et al.*, 1996). On the other hand, total plasma protein and albumin was significantly decreased in all drug-treated groups. Liver synthesizes plasma protein (Ganong, 2006) and lower protein level has been reported in compromised liver functions (Bass, 2003). The decrease in the serum albumin and total protein may also indicate to the renal inability keeps it in; therefore it excreted with urine (Albumiurea) (Vasilenko and Grebenev, 1990). Thus, the penicillin and streptomycin altered the synthetic function of the liver. In conjunction with the reports of (Hegde and Joshi, 2009; Kim *et al.*, 2010), data from the present study showed that penicillin and streptomycin caused hepatic damage with a significant increase in serum levels of ASAT, ALT and ALP and decrease in serum levels of total protein and albumin level is also related to the status and function of hepatic cells. penicillin and streptomycin administration in the present study also caused significant increase in the serum ALP which may be due to increased synthesis in presence of increasing biliary pressure (Moss and Butterworth, 1974). The distortion of the radial arrangement of the sinusoids from the central vein, the distortion of the hexagonal shape of the hepatocytes with evidence of hepatic necrosis may be due to the cleaving of sialic acid by the enzyme sialidase from the haemoglobin-free erythrocytes, plasma and the liver, thus exposing the liver to the damage noticed (Wilson *et al.*, 2011). Thus, our results demonstrate effect penicillin and Streptomycin on Hepatotoxicity, and this is consistent with (Walter *et al.*, 1996; James *et al.*, 1998; Janker *et al.*, 2005; Brahin, 2008; Akande *et al.*, 2012). However, the activities of these enzymes were reduced after the treatment by honey bee (groups 3 and 5), when compared to penicillin and streptomycin treated rats alone. The penicillin and streptomycin induced oxidative stress was lowered. On hypothesis to explain the beneficial effects of honey in ameliorating biochemical parameters and histological changes is that honey may contains flavonoids, ascorbic acid, tocopherols, catalase and phenolic compounds. All of which work together to provide a synergistic antioxidant effect, scavenging and eliminating free radicals (Johnston *et al.*, 2005). and in Recently, it has been found that honey leads to increased levels of total protein and albumin in biological fluids and to reduced liver enzymes, such as AST, ALT and ALP, in blood (Al-Waili *et al.*, 2006). plus honey group showed significant improvement in liver tissues. Our results showed the protective potential of honey with liver damage. Thus, our results demonstrate protective effect of nabk honey Hepatotoxicity, and this is consistent with (Mohamed, 2005;

Abdel-Moneim and Ghafeer, 2007; Ismael and Ashour, 2007; Khadr *et al.*, 2007; El-Khayat, 2009; Eminatedoki *et al.*, 2010). In conclusion, we suggest that honey supplementation may give beneficial results in the prevention of hepatic damage induced by the use of antibiotics (penicillin and streptomycin).

REFERENCES

- Abas HM. The study is designed to investigate the antimutagenic effects of natural honey through the studying of the role of honey in the inhibiting of toxic and genotoxic effect of a rodenticide Brodifacoum on somatic cells and germ cells in mice *Mus musculus*. J. Univer. Babel. 2010; 18: 1922-1933.
- Abdel-Moneim WM & Ghafeer HH. The potential protective effect of natural honey against cadmium-induced hepatotoxicity and Nephrotoxicity. *Mansoura J. Forensic Med. Clin. Toxicol.* 2007; 12: 75-98.
- Akande T, Balogun ST & Gabriel O. The effects of penicillin streptomycin on liver aminotransferases, alkaline phosphatase and total serum protein in rabbits (*Oryctolagus coniculus*), *Journal of Applied Pharmaceutical Science*. 2012; 2: 32-35.
- Al-Waili NS, Saloom KY, Akmal M, Al-Waili F, Al-Waili TN, Al-Waili AN & Ali A. Honey ameliorates influence of hemorrhage and food restriction on renal and hepatic functions, and hematological and biochemical variables. *Int J Food Sci Nutr.* 2006; 57: 353-362.
- Bakke OM, Manocchia MA, de Abajo F, Kaitin K, & Lasagna L. Drug safety discontinuations in the United Kingdom, the United States, and Spain from 1974 through 1993: a regulatory perspective. *Clinical Pharmacology & Therapeutics.* 1995; 58:108-117.
- Barry AL. Antimicrobial resistance among clinical isolates of *Streptococcus pneumoniae* in North America. *American Journal of Medicine.* 1999; 107: 335-385.
- Bass NM. Drug-induced liver diseases. 2003. In: Friedmaus MC, Quaidk, Grendell J (eds). *Current diagnosis and treatment in gastroenterology* (2nd ed). (pp. 664-679). New York, NY: McGraw- Hill Professional.
- Benjamin MN. 1978. *Outline of veterinary Clinical Pathology.* University press. Iowa. 229-232.
- Berretta G, Granata P, Ferrero M, Orioli M and Facino RM. Standardization of antioxidant properties of honey by combination of spectrophotometric/fluorometric assays and chemometrics. *Anal. Chim. Acta.* 2005; 533: 185-191.
- Bilsel Y, Bugra D, Yamaner S, Bulut T, Cevikbas U and Turkoglu U. Could honey have a place in colitis therapy? Effects of honey, prednisolone, and disulfiram on inflammation, nitric oxide, and free radical formation. *Dig. Surg.* 2002; 19: 306-312.
- Bishop Y. 2006. *Drug interaction. The Veterinary Formulary* (16th ed). London: The Pharmaceutical Press. 499-519.
- Brahin MR. Liver Function damage in long-term streptomycin therapy in male rats. *J. clin. Biochem.* 2008; 11: 50-56.
- Brunton L, Parker K, Blumenthal D and Buxton I. 2008. *General principles of antimicrobial therapy. Goodman & Gilman's Manual of Pharmacology & Therapeutics.* New York: The McGraw-Hill companies, Inc. 2008; 711-712.
- Doumas BT, Watson WA and Homer CB. Albumin standard and measurement of the albumin with bromocresol green, *Clin Chem Acta.* 1971; 31: 87-96.
- Elizabeth P. Antonio J. Rodriguez-Malaver I and Patricia V. Antioxidant Capacity of Venezuelan Honey in Wistar Rat Homogenates. *J Med Food.* 2006; 9: 510-516
- El-Khayat Z, Ezzat A, Arbid M, Rasheed W and Elias T. Potential Effects of Bee Honey and Propolis Against the Toxicity of Ochratoxin A in Rats. *Macedo.* 2009; *J. Medi. Sci.* 15:311-318.
- Eminatedoki DG, Uwakwe AA and Gloria OI. Protective effect of *Garcinia kola* seed and honey against paracetamol-induced hepatotoxicity in rat. *J. Biochem and Molecular Biolo.* 2010; 25: 80-90.
- Friedland IR, Paris M, Shelton S and Mc Craken GH. Timekilling studies of antibiotic combination against penicillin-resistant and susceptible *Streptococcus pneumoniae*. *Journal of Antimicrobial and*

Chemotherapy 1994; 34:231-237.

Ganong WF. 2006. Gastrointestinal tract functions. Review of Medical Physiology (22nd ed). New York: The McGraw-Hill companies, Inc. 210-231.

Garba SH, Prasad J and Sandabe UK. Histomorphological Effect of the Aqueous Root-Bark Extract of *Ficus sycomorus* (Linn) on the Liver and Kidney of Albino Rats. *Interna. J. Pharma.* 2006; 2: 628-632.

Garba. SH, Sambo N, and Bala U. The Effect of the Aqueous Extract of *Kohautia Grandiflora* on Paracetamol Induced Liver Damage in Albino Rats. *Nig. J. Physiol. Sci.* 2009; 24: 17-23.

Gharzouli K, Gharzoul A, Amira A and Khennouf S. Protective effect of mannitol, glucose-fructose-sucrose-maltose mixture, and natural honey hyperosmolar solutions against ethanol-induced gastric mucosal damage in rats. *Exper. Toxicol. Pathology.* 2001; 53: 175-180.

Guinea Pigs Care Sheet. Canyon Lake Veterinary Hospital. Retrieved (2007) 02-04.

Halliwell B, Gutteridge JM and Cross CE. Free radicals, antioxidants, and human disease: where are we now. *J. Lab. Clin. Med.* 1992; 119: 598-620.

Hansten PD. 1998. Important drug interaction and their mechanisms. In Katzung B.G (ed) *Basic and Clinical Pharmacology* (7th ed) 1060. Connecticut: Apple & Lange.

Harold AT. penicillin in benign late and Visceral Syphilis in rats. *Amer. J. Med.* 1998 5(5) :702 – 708.

Health, Care and Diet for a Guinea pig. Lake Howell Animal Clinic. Retrieved 2007-02-16: 526-534.

Hegde K and Joshi AB. Hepatoprotective effect of *Carissa carandas* Linn root extract against CCl₄ and paracetamol induced hepatic oxidative stress. *Indian J. Exp. Biol.* 2009; 47: 660-667.

Humason GL. 1979. Animal tissue techniques. (2nd ed). Freeman WH, and Company. 661.

Ismael A and Ashour E. Biochemical studies on albino rats after administration of nitrosamine and the therapeutic actions of vitamin C, honey bee or crushed citrus seeds. *The Islamic University.* 2007; J. 15: 177-188.

James E, Robert F, Dalores F and Nancy S. Acute Upper Respiratory Disease :treatment with penicillin. *J. Pediatr.* 1998 ; 53: 571 – 578.

Janker MN, Ribati SS and Furan JA. Hepatotoxicity of streptomycin. *J Exp. Biochem.* 2005; 27: 67-73.

Johnston J, Sepe H, Miano C, Brannan R and Alderton A. Honey inhibits lipid oxidation in ready-to-eat ground beef patties. *Meat Science.* 2005; 70: 627-631.

Jones R and Pfaller M. Bacterial resistance: a worldwide problem. *Diagnostic Microbiology & Infectious Diseases.* 1998; 31:379-388.

Khadr ME, Mahdy KA, El-Shamy KA, Morsy FA, El-Zayat SR and Abd-Allah AA. Antioxidant activity and hepatoprotective potential of black seed, honey and silymarin on experimental liver injuries induced by paracetamol in rat. *J. Appl. Sci.* 2007; 7:3909-3917.

Kim HY, Kim JK, Choi JH, Jung JY, Oh WY, Kim DC, Lee HS, Kim YS, Kang SS, Lee SH and Lee SM. Hepatoprotective effect of pinoresinol on carbon tetrachloride-induced hepatic damage in mice. *J. Pharmacol. Sci.* 2010; 112:105- 112.

Kind PR, King EG. Estimation of plasma phosphate by determination of hydrolyzed phenol with amino-antpyrine, *J Clin Path.* 1954; 7: 56-63.

Kumar AN, Abbas AK, Fausto N. Robbins and Cotran. 2004. *Pathologic Basis of Disease.* 7th ed. Saunders Elsevier, Philadelphia. 48-51.

Lee WM. Drug-induced hepatotoxicity. *New England Journal of Medicine.* 2003; 349:474-485.

Mato I, Huidobro JF, Simal-Lozano J and Sancho MT. Significance of nonaromatic organic acids in honey. *J. Food Prot.* 2003; 66: 2371-2376.

Michalkiewicz A, Biesaga M and Pырzyska K. Solid-phase extraction procedure for determination of phenolic acids and some flavonols in honey. *J. Chromatogr. A.* 2008; 1187: 18-24.

Mohamed E. effect of honey histological changes in mice following exposure doxorubicin. *J. Invero. Toxicol.* 2005; 25: 123-131.

Moss DW and Butterworth PJ. 1974. *Enzymology and Medicine.* Pitman Medical, London . 139.

Pari L and Kumar AN. Hepatoprotective activity of *Moringa oleifera* on antitubercular drug induced liver damage in rats. *J. Med.* 2002; 5: 171- 177.

Pari L and Murugan P. Protective role of tetrahydrocurcumin against erythromycin estolate-induced hepatotoxicity. *Pharmacol. Res.* 2004; 49:481-486

Perez E, Rodriguez-Malaver AJ and Vit P. Antioxidant capacity of Venezuelan honey in wistar rat homogenates. *J. Med. Food.* 2006; 9: 510-516.

Pratt DS and Kaplan MM. Evaluation of abnormal liver enzyme results in asymptomatic patients. *New England J. Medi.* 2000; 342:1266-1271

Reitman SS and Frankel SA. colorimetric method for glutamic-pyruvate transaminase, *Am J Clin Path.* 1975; 28: 56-63.

Rossi S. *Australian Medicine Handbook.* Adelaide: Australian Medical Association. 2004, 145-155.

Rowland M and Tozer TN. 1989. *Clinical Pharmacokinetics: Concepts and Applications,* 3rd ed. Lea, Febiger: Philadelphia. 148-160.

Sallie R, Tredger JM and Willaim R. *Drugs and the liver.* Biopharmace and Drug Disposition. 1991; 12: 251- 259.

Singh I. 1980. In: *Textbook of Biochemistry and Human Biology.* Talwar, G. P. (ed.), Prentice Hall of India, New Delhi. 201-203.

Tan HT, Rahman RA, Gan SH, Halim AS, Hassan SA, Sulaiman SA and Kirnpal-Kaur B. The antibacterial properties of Malaysian tualang honey against wound and enteric microorganisms in comparison to manuka honey. *BMC Complement. Altern. Med.* 2009; 9: 34.

Tietz NW. Biuret method for the determination of total protein in serum In: *Fundamental of clinical chemistry.* WBS Saunders Co. Philadelphia, Toronto, London (1976) 503 and 879.

Udeani TK and Kalu SI. Comparison of penicillin and streptomycin in treatment of *Streptococcus pneumoniae* infection in mice. *Nigerian Journal of Experimental & Applied Biology.* 2003; 2: 45-50.

Vosilinko V and Grebenev A. 1990. *Internal diseases.* Mir. Pub. Moscow. 406.

Walter S, Antonio B and Ruedi L. Aminoglycoside antibiotics in infectious diseases *Amer. J. Med.* 1996; 80: 2 -14.

Whitby LG, Percy-Robb IW and Smith AF.. Examples of clinically important plasma enzymes. *Lecture notes on Clinical Chemistry.* 1984, 141-150.

Williamson EM, Okpako DT and Evans FJ. Selection, preparation and pharmacological evaluation of plant material, John Wiley, England (1996) 13.

Wilson JI, George BO and Umukoro GE. Effects of honey on the histology of liver in adult Westar rats. *Bio and Medi.* 2011; 3: 1-5.

Wittwer FM and Bohmwald LH. 1986. *Manuel de Patologia Clinica Veterinaria.* Valdivia Chile. 53-93.

How to cite this article:

Mohammed S.A.Al-Awar, Elham A. S. AL- Shaibani, Elias M.A.Salih, Mohammed A.Y.Al-Eryani., The Protective Effect of Nabk Honey against Pathological Effects of Penicillin and Streptomycin on Histological Structure and Functions of Guinea pigs Liver. *J App Pharm Sci,* 2013; 3 (4 Suppl 1): S1-S6.