



ISSN: 2231-3354
Received on: 06-11-2011
Revised on: 15-11-2011
Accepted on: 20-11-2011

Effect of alkaloids extract of *Gnetum africanum* on serum enzymes levels in albino rats

Francis V. Udoh, Albert. P. Ekanem and Patrick. E. Ebong

Francis V. Udoh
Department of Pharmacology,
University of Calabar,
Calabar, Nigeria.

Albert. P. Ekanem
Institute of Oceanography,
University of Calabar,
Calabar, Nigeria.

Patrick. E. Ebong
Department of Biochemistry,
University of Calabar,
Calabar, Nigeria.

ABSTRACT

Alkaloids extract of the leaf of *Gnetum africanum* pretreatment was investigated on the activities of aspartate amino transaminase (AST), alanine amino transaminase (ALT) and alkaline phosphatase (ALP) serum and tissue levels in rats. The alkaloids extract was soxhlet extracted following a modified standard procedure. Acute toxicity of the extract was carried out in male rats to determine two tolerated doses used in investigation. Thirty adult male rats were divided into three groups (n=10). Group one received normal saline (0.85%NaCl) as control; groups two and three received alkaloids extract of *Gnetum africanum*, 12 and 800mg/kg/d, for 3 and 31 days respectively. At the end of each treatment course, the rats were sacrificed 24h after last dose and blood samples collected through cardiac puncture into non-heparinized tubes, allowed to clot for 30 min and sera obtained by ultra iced-centrifugation. The biological activities of AST, ALT and ALP were measured by enzyme kits method. Histopathology of rat liver tissues of all treated groups were carried out. The alkaloids extract pretreatment for 3 days did not significantly alter serum and tissue enzymes levels of AST and ALT but significantly reduced the activity of ALP. However, subchronic treatments for 31 days significantly reversed the inhibitory effect of the extract on AST, ALT and ALP respectively. Histopathology of the rat liver morphology of all the treated groups showed no disorder. The observation allows conclusion that alkaloids extract of the leaf of *Gnetum africanum* is non hepatotoxic.

Keywords: Alkaloid extract, *Gnetum africanum*, serum enzymes, albino rats.

INTRODUCTION

The plant, identified as *Gnetum africanum* (family, Gnetaceae) is locally called “afang” by the people of Akwa Ibom and Cross River State of Nigeria. It is a wild climbing plant with dark green leaves tasting sweet or slightly bitter when eaten. The leaves of the plant serves as vegetable mixed with the leaves of *Talinum triangular* (water leaf) as an additive (Akpanabiatus *et al.*, 1998). Naturally, the leaf of *G. africanum* is considered superior to all other vegetables to most people of the Niger Delta of Nigeria. Phytochemistry of the leaves of the plant revealed that, it is an important source of protein, essential amino acids and mineral elements (Baker, 1972). The leaves of the plant are also used in the Nigeria herbal medicine for the treatment of enlarged spleen, sore throats and as a cathartic (Abdullah *et al.*, 1989). Pharmacological study (unpublished) has shown that the leaf extract of the plant has a potential phytoestrogenic activity which could interfere with some biochemical functions of the liver. The objective of the study was to investigate the effect of alkaloids extract of *G. africanum* on serum enzymes level in albino rats.

MATERIALS AND METHODS

Preparation of plant extract

The fresh leaves of *G. africanum* were bought from Watt Market in Calabar, Cross River State, Nigeria during the Months of March and April, 2009. The plant was authenticated by

For Correspondence
Albert. P. Ekanem
Institute of Oceanography,
University of Calabar, Calabar,
Nigeria.

Professor. Ani Nkang of the Department of Botany, University of Calabar. The Voucher specimen was preserved in the Herbarium of the Department of Botany, University of Calabr, Nigeria.

The leaves of the plant were washed to remove debris and dried overnight at room temperature ($28 \pm 1^\circ\text{C}$). The dry leaves of the plant were sliced and ground into powder using an electric Blender (Behrmaning Trog, N.Y.).

About 100g of the powder was wrapped in a thimble and placed in 500ml soxhlet extractor; extracted first in petroleum ether for 8h. The petroleum ether extract solution was decanted and the residues left in the soxhlet extractor were re-extracted in absolute ethanol for 72h. The ethanolic extract solution was evaporated using a rotary evaporator *in vacuo* at a reduced temperature of 40°C . The leaf extract weighing 40g was dissolved in equal volumes of chloroform and water mixture, mixed and allowed to stand overnight and separate into chloroform and water fractions. Chloroform fraction was discarded and water fraction was evaporated into powder extract, using rotary evaporator (Mol G Scientific Company, England). The water extract fraction was photochemically tested to contain alkaloids and a negligible amount of tannins.

Treatment

Three test doses of alkaloids extract of the leaf of *G. africanum* were administered orally to three groups of female rats ($n=5$). Group 1, 2 and 3 received alkaloids extract (10, 200 and 700 mg/kg/d) respectively and group 4 received 2ml of normal saline as control, for 3 days. On the 4th day rats from all the groups were sacrificed.

Preparation of serum

Rats of all the groups were anaesthetized with chloroform and blood samples were collected from the animals through cardiac puncture into centrifugal tubes and allowed to clot for 30 minutes. The clotted blood samples were centrifuged to separate the cells from the serum. Sera were then aspirated into labeled vials and stored in the freezer at -15°C until ready to use.

Enzymes assays

Serum levels of aspartate aminotransferase (AST), alanine aminotransferase (ALT) and alkaline phosphatase (ALP) were measured by spectrophotometric method. Activities of enzymes were estimated from the standard calibration curves using a modified method described by Akpanabiatu et al (2006).

Tissue levels of AST, ALT and ALP of the test animals were estimated in iced liver tissue homogenates following the method described by Udo (2007; Feray, 2010), the US National Cancer Institute, 2011.

Histopathology

The liver tissues isolated from the test animals were fixed in formal-saline for 48h. The fixed tissue were processed manually through graded ethanol, cleared in xylene, impregnated and embedded in paraffin wax. Thin sections were cut with a rotary

microtome, stained by haematoxylin and eosin technique, examined microscopically for pathological changes.

Statistical Analysis

Data obtained from this work were analysed statistically using the one-way analysis of variance (ANOVA), followed by a post test multiple comparison (Turkey-Kramer multiple comparison test). Differences between means were considered significant at 1% and 5% of significance ($P < 0.01$ and 0.05).

RESULTS

Serum enzyme levels

The alkaloids extract of the leaf of *Gnetum africanum* (10 and 700 mg/kg) treatment daily for 7 days resulted in the significant ($P < 0.01$) increase serum activities of aspartate aminotransaminase (AST) and alkaline phosphatase (ALP) in rats (Table 1). However, serum activities of alanine aminotransferase (ALT) was not significantly ($P > 0.05$) inhibited by the chronic treatment with the alkaloids extract of *G. africanum* (10 and 700 mg/kg) daily for 30 days (Table 1). Conversely, acute treatment with the alkaloids extract (700mg/kg/d) of extract for 3 days significantly ($P < 0.01$) induced serum ALT activity in rats (Table 1).

Table 1. Effect of alkaloids extract of *Gnetum africanum* repeated treatment, daily for 3 and 30 days on serum activity of aspartate aminotransaminase (AST), alanine aminotransaminase (ALT), and alkaline phosphatase (ALP) in albino rats.

Treatment dose (mg/kg)	Serum Enzymes Levels (μl)					
	AST		ALT		ALP	
	D3	D30	D3	D30	D3	D30
Control 2ml 0.85% Nacl	22 \pm 1.2	22 \pm 1.2	10.3 \pm 0.7	10.3 \pm 0.7	39.7 \pm 1.4	39.7 \pm 1.4
AE (10)	36.3* \pm 0.1	30* \pm 1	11.3 \pm 1	8 \pm 0.7	81.7* \pm 2	60* \pm 1.8
AE (200)	32.1* \pm 0.1	31* \pm 1	9.1 \pm 0.1	8 \pm 0.1	89* \pm 1	70* \pm 1
AE (700)	29.1* \pm 1	30* \pm 1	10 \pm 0.7	10.7 \pm 1	87.3* \pm 2	45 \pm 1.7

* $p < 0.01$, by student t-test compared with control
 D3 = 3day treatment with extract
 D30 = 30 day treatment with extract
 AE = Alkaloids extract
 *P = significant level

Table 2. Effect of alkaloids extract of *Gnetum africanum* daily treatment for 3 and 30 days on liver tissue enzymes levels.

Treatment dose (mg/kg)	Liver Tissue Enzymes Levels (μl)					
	AST		ALT		ALP	
	D3	D30	D3	D30	D3	D30
Control (2ml 0.85% Nacl)	199.5 \pm 14	199.5 \pm 14	177 \pm 6	177 \pm 6	329 \pm 30	329 \pm 30
AE (10)	198.1 \pm 3	182*.1 \pm 5	114 \pm 2	116 \pm 1	267* \pm 21	265 \pm 1
AE (200)	1995.1 \pm 5	181.9* \pm 4	115 \pm 1	116 \pm 1	288* \pm 26	287* \pm 2
AE (700)	197.6 \pm 8	181.9* \pm 1	115 \pm 1	115 \pm 1	288* \pm 26	258* \pm 4

* $p < 0.05$, by student t-test compared with control
 D3 = 3days' treatment with extract
 D30 = 30 days' treatment with extract
 AE = Alkaloids extract
 AST = Aspartate aminotransaminase
 ALT = Alanine aminotransaminase
 ALP = Alkaline phosphate
 *P = significant level

Numerical after AE = Dose in mg/kg body weight

Liver tissue enzyme levels

Acute treatment of rats with varying doses of the extract did not significantly ($P < 0.05$) alter the liver tissue activity of ALT, while the activities of AST were significantly inhibited in the test groups when compared to controls (Table 2). However, chronic and acute treatments with the extract induced significant decrease ($P < 0.01$) liver tissue ALP activities as compared to the controls.

Liver tissue morphology

The varying doses of alkaloids extract (10, 200 and 700 mg/kg/d) of *G. africanum* leaves administered orally to rats for 3 and 30 days did not induce pathologic changes in the morphology of the liver cells of the test animals when compared to the control (Fig.1).

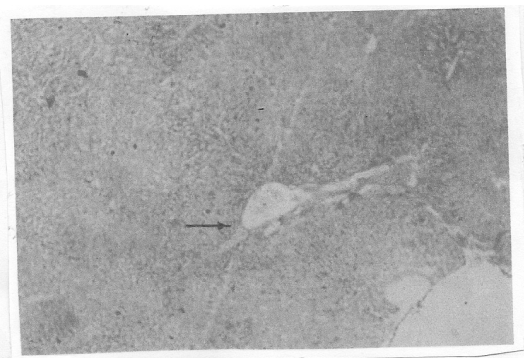


Fig. 1. Photomicrograph of the cross section of liver of rat treated with normal saline daily for thirty days as control (H&E). Arrow shows normal hepatic portal vein (X40).

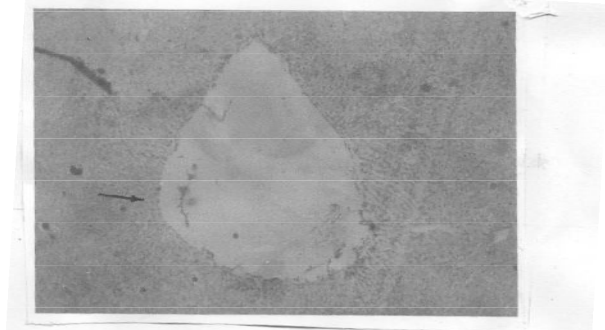


Fig. 2. photomicrograph of the cross section of liver from rat treated with the alkaloids extract of *Gnetum africanum*, 10mg/kg/d for 3 days (H&E). Arrow shows pronounced dilatation of the hepatic portal vein (X40).

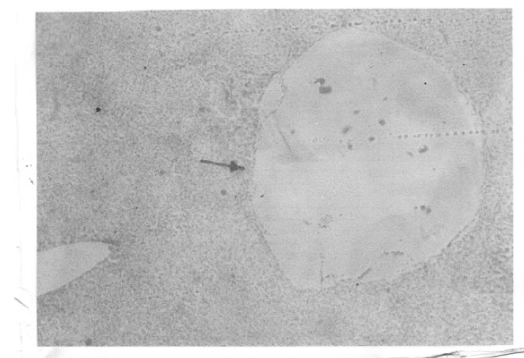


Fig. 3. Photomicrograph of the cross section of liver from rat treated with the alkaloids extract of *Gnetum africanum*, 10mg/kg/d for 30 days (H&E). Arrow shows pronounced dilatation of the hepatic portal vein (X40).

However, acute and chronic treatments daily for 3 and 30 days with the alkaloids extract (10, 200 and 700 mg/kg) of extract induced central portal vein dilatation as shown in the figures 2 and 3.

DISCUSSION

Investigation of the effects of administration of the alkaloids extract from the leaf of *G. africanum* on the serum and tissue levels of aspartate aminotransferase (AST), alanin aminotransferase (ALT) and alkaline phosphatase (ALP) revealed that acute treatments for 3 days with the plant extract resulted in a sharp rise in the serum enzyme levels. The sharp rise was attenuated gradually following repeated (subchronic) administration over a period of 30 days. On the other hand, acute treatment for 3 days caused significant ($P > 0.01$) reduction in the tissue levels of ALT, AST and ALP respectively. Graded reduction in the magnitude of increase in serum and tissue enzymes activity following subchronic treatment for 30 days might be an indication of negative feed back effect. This phenomenon was similar to the negative feed back mechanism involving the release of hormones (Bowman and Rand, 1980).

The sharp rise in the enzyme serum levels could probably be due to sudden physiological changes following acute extract tissue interaction and not necessarily pathological. It has been reported that some substances are capable of inducing enzymes such as cytochrome P450, monooxygenase, monoamine oxidase and other enzymes (Bowman and Rand, 1980; Dibase et al, 2010). These observations showed that acute administration of the alkaloids extract from the leaf of *G. africanum* could stimulate the release of some enzymes into serum which could influence extrahepatic metabolism of certain substances or drug biotransformation.

Repeated (subchronic) administration of *G. africanum* extracts for 30 days did not cause any increase in serum and liver tissue-homogenate enzymes levels compared to enzymes levels due to acute treatment for 3 days. These findings led to the suggestion that extract of the leaf of *G. africanum* is not hepatotoxic.

REFERENCES

- Abdullah, T. H, Kirpatrick D.V & Carter, J. Enhancement of natural killer cell activity in AIDS with garlic. *Dtsch Z Onkol.* 1989; 21, 52.
- Akpanabiatu, M. I., Basse, N. B., Udosen, E. O. and Eyong, E. U. Evaluation of some minerals and toxicants in some Nigerian soup meals. *Journal of Food Composition and Analysis.* 1998;11, 292-297.
- Akpanabiatu, M. I., Umoh, I. B., Enyong, E. E., Edet, E. E. & Udoh, D. E. Influence of *Rauwolfia vomitoria*. Root bark extract and cardiac enzymes of normal Wistar, albino rats. Recent progress in medicinal plants. *Biopharmaceuticals.* 2006;14, 273-278.
- Baker, H. G. *Plant and Civilization.* London: Macmillan, (1972) 110.
- Bowman, W. C. & Rand M. J. (1989). The endocrine system and drug affecting endocrine function. In W. C. Bowman and M. J. Rand (Eds), *Textbook of Pharmacology* (2nd ed) (P.19. 1-64). Oxford: Blackwell scientific Publications.
- DiBiase A. R., Colechia, A., Scaioli, E., Berii, R., Viola, L., Vestito, A., Balli, F. and Festi, D. Autoimmune liver diseases in a paediatric population with coeliac disease a 10-year single centre

experience. *International Journal of Gastroenterology and Hepatology*. 2010;31 (2) 253-259.

Feray, C. Towards predicting the therapeutic response in patients with hepatitis C. *International Journal of Gastroenterology and Hepatology*. 2010;31 (2) 339-343.

The US National Cancer Institute. The Us National Cancer Institute, Surveillance Epidemiology and End Results (SEER) data base,

1973-2006. Published at: <http://seer.cancer.gov> (assessed on April, 2011).

Udoh, F. V. (2007). The effects of *Gnetum africanum* leaf extracts on some biochemical indices and endocrine functions in albino rats. A PhD thesis by F. V. Udoh submitted to Graduate School, University of Calabar, Nigeria, P. 150.