

Hepatoprotective activity of *Parmelia perlata* (Huds.) Ach. against CCl₄ induced liver toxicity in Albino Wistar rats

Sunita Shailajan*, Mayuresh Joshi, Bhavesh Tiwari

Herbal Research Lab, Ramnarain Ruia College, Matunga (East), Mumbai – 400 019, India.

ARTICLE INFO

Article history:

Received on: 15/01/2014

Revised on: 12/02/2014

Accepted on: 24/02/2014

Available online: 27/02/2014

Key words:

Lichen, *Parmelia perlata*,
Hepatoprotection, Carbon
tetrachloride

ABSTRACT

Many plants have been claimed to possess liver protecting activity. But, due to scarcity of potent modern medicine to treat severe liver diseases, many folk remedies of plant origin have been scientifically evaluated for their potential hepatoprotective activity in experimental animal models. *Parmelia perlata* (Huds.) Ach. (lichen, Parmeliaceae), commonly known as Dagad phool or stone flower in India, is mentioned in *Indian Materia Medica* as useful in treating a number of ailments. In the present study, hepatoprotective activity of aqueous slurry of *P. perlata* was investigated in CCl₄ intoxicated Albino Wistar rats and the results were compared with, Silymarin. Intraperitoneal injection of CCl₄, produced a marked elevation in the level of biochemical markers such as Serum Glutamate Oxaloacetate Transaminase (SGOT), Serum Glutamate Pyruvate Transaminase (SGPT), bilirubin, cholesterol and triglycerides. Oral administration of *P. perlata* aqueous slurry at 0.7 g / kg and 1.0 g / kg in CCl₄ intoxicated rats showed marked decrease in the level of biochemical markers and results were at par with the effect shown by Silymarin. The results of histopathological analysis were in compliance with the findings of blood biochemical parameter analysis. This study confirms that *P. perlata* aqueous slurry has phyto-components with hepatoprotective potential.

INTRODUCTION

The prevalence of hepatopathy in the world indicates an increased incidence rate with severe consequences on the liver (Adefolaju *et al.*, 2009). Herbal drugs are more widely used than allopathic drugs as hepatoprotectives because they are inexpensive, have better cultural acceptability, better compatibility with the human body and minimal side effects. Nearly 150 phytoconstituents from 101 plants have been claimed to possess liver protecting activity (Subramoniam and Pushpangadan, 1999). Therefore, many folk remedies from plant origin are being tested for their potential hepatoprotective activity in experimental animal models (Ganga Rao *et al.*, 2012). One of the commonly used *in-vivo* models for investigating new hepatoprotective agents is liver injury induced by carbon tetrachloride (CCl₄), a chemical hepatotoxin that causes a free radical-mediated hepatic cellular damage (Chen *et al.*, 2009; Roy *et al.*, 2011). Several plants like *Solanum xanthocarpum* (Gupta *et al.*, 2012), *Spilanthes acmella* (Ganga Rao *et al.*, 2012), *Ardisia solanacea* (Samal, 2013),

Adiantum incisum (Frank *et al.*, 2012) etc. have been reported to possess hepatoprotective activity against CCl₄ induced hepatotoxicity. Similarly, some lichens like *Usnea ghattensis* have been reported to possess antioxidant and hepatoprotective activity against ethanol induced hepatotoxicity (Verma *et al.*, 2008).

Parmelia perlata (Huds.) Ach. (lichen, Parmeliaceae), commonly known as Dagad phool or stone flower in India, is mentioned in *Indian Materia Medica* as useful in treating a number of ailments (Halama and Haluwin, 2004). It is collected and consumed in large quantities as a food supplement in India. *P. perlata* is used to treat wounds, infections, inflammation, skin diseases, diarrhoea, dysentery, cough, fever and renal calculi (Tay *et al.*, 2004).

It has also been reported to possess antimicrobial (Thippeswamy, 2012), Anti-viral (Esimone *et al.*, 2007), antioxidant activity (Patil *et al.*, 2011) along with its analgesic, antipyretic (Muller, 2001) and antispasmodic potential (Correia, 1976). Thus, the present study is aimed to evaluate the hepatoprotective activity of aqueous slurry of *P. perlata* against CCl₄ induced hepatotoxicity in rats. The efficacy has been compared with the known hepatoprotectant, Silymarin.

* Corresponding Author

Dr. Sunita Shailajan,

Tel.: +91 2224154390; fax: +91 2224142480.

E-mail: sunitashailajan@gmail.com

MATERIALS AND METHODS

Plant material

P. perlata was collected from local market (Thane, Maharashtra) and the herbarium of the sample was authenticated (AUTH/HRL/12-04). Sample was carefully segregated, cleaned and oven dried at 37° C to constant weight, powdered, sieved (BSS 85) and stored in airtight containers.

Drugs and chemicals

CCl₄ (GR grade, Batch no.: IG8G580178, Merck Specialties Pvt. Ltd) and Silybon tablets (Silymarin as silybin 70 mg, Batch no. SIAD0025, Micro Labs Limited) were procured from market. All other chemicals used were of analytical grade.

Quality control

The quality of the sample was evaluated for foreign matter, total ash, acid insoluble ash, alcohol soluble extractive and water-soluble extractive. The results were compared with those mentioned in API.

Animals

Adult albino Wistar rats (female 200-250 g) and Swiss Albino mice (18-22 g) procured from Haffkin Biopharmaceuticals, Parel, Mumbai were used in this study. The animals were maintained under standard laboratory conditions at an ambient temperature of 25 ± 2° C with 12-h light and dark cycle in an animal house with standard facilities under CPCSE approvals. They were fed with rat feed (AMRUT feed) and water *ad libitum*.

Preparation of aqueous slurry

Aqueous slurry of *P. perlata* was prepared by mixing appropriately weighed powdered material in distilled water. The animals were dosed individually as per their body weights.

Safety evaluation

Safety study of *P. perlata* aqueous slurry was conducted in mice as per OECD guidelines (No. 420, fixed dose procedure). The mice were fasted overnight for 10-14 hours and administered with aqueous slurry of *P. perlata* (2.0 g/kg) orally. The animals were observed individually during the first 30 min for all reflexes, periodically during the first 48 hours with special attention given during the first 4 hours (short-term toxicity) and daily thereafter for a total of 14 days (long-term toxicity) for alteration from general behavior and clinical symptoms like alteration of skin and fur texture, ptosis, excessive salivation, breathing problems, diarrhea etc. Daily body weight, food and water intake record was also maintained. The results were compared with control group (orally administered with DW).

Assessment of hepatoprotective activity against CCl₄ induced liver intoxication

Carbon tetrachloride intoxication in rats is an experimental model widely used to study necrosis and pathophysiological status

of liver (Rao *et al.*, 2012). In this study, albino Wistar rats were randomly divided into 6 groups with six animals in each. The group details are as follows:

- **Group I:** Normal control
- **Group II:** CCl₄ control (1.2 ml/kg)
- **Group III:** CCl₄ control as natural recovery group
- **Group IV:** CCl₄ control treated with daily dose of Silymarin (0.070 g/kg b.w.)
- **Group V:** CCl₄ control treated with daily dose of *P. perlata* aqueous slurry (0.7 g/kg b.w.)
- **Group VI:** CCl₄ control treated with daily dose of *P. perlata* aqueous slurry (1.0 g/kg b.w.)

The animals were fasted overnight before the initiation of the study. Animals from Group I received an intraperitoneal injection of 0.5 ml liquid paraffin/animal on the first day of the study and were treated as normal control. Those from Groups II, III, IV, V and VI received an intraperitoneal injection of 1.2 ml/kg CCl₄ (Koh *et al.*, 2011; Nayak *et al.*, 2008) in 0.5 ml liquid paraffin/animal on the first day of the study. The animals from Groups I, II and III received an oral dose of 2 ml of distilled water (D/W) once daily. A dose of 0.07 g / kg Silymarin (Silymarin clinical update, 1995) (in the form of Silybon tablets) suspended in 2 ml of D/W was administered orally to each animal of Group IV once daily and one hour post induction on the first day. The animals from Group V and VI received an oral dose of *P. perlata* aqueous slurry (0.7 g / kg and 1.0 g / kg respectively) / animal daily and one hour post induction on the first day. The animals from Groups I, II, IV, V and VI were sacrificed on the fourth day (72 hr after dosing) and those from Group III were sacrificed on seventh day of the study for comparative evaluation of the natural recovery in the study. Daily record of body weight and food and water intake was also maintained.

Prior to the sacrifice, 2 ml blood was collected from retro orbital plexus in non-heparinized vials. Blood was centrifuged at 5000 rpm for 8 mins and serum was separated. Biochemical parameters like Serum Glutamate Oxaloacetate Transaminase (SGOT), Serum Glutamate Pyruvate Transaminase (SGPT), Total Bilirubin, Cholesterol and Triglycerides were analyzed from the serum samples obtained. During autopsy, liver was excised, rinsed in saline, blotted and weighed. A small piece of liver tissue from the largest lobe was cut and fixed into bouin's fixative. Fixed tissues were processed for routine haematoxylin and eosin staining and evaluated. The extent of liver recovery was compared with known hepatoprotectant, Silymarin. Percent protection in individual biochemical parameters from their elevated values caused by the hepatoprotection was calculated as $100 \times (\text{values of CCl}_4 \text{ Control} - \text{values of sample}) / (\text{values of CCl}_4 \text{ control} - \text{values of vehicle})$ (Ganga Rao *et al.*, 2012).

Statistical analysis

All values were expressed as mean ± S.E and statistically analyzed for significance using Dunnett's test, comparing group I

with the other groups using graph pad prism 5 software. $P \leq 0.05$ was considered as statistically significant.

RESULTS AND DISCUSSION

Medicinal plants and their derivatives have been used since ancient time in various forms for the treatment of liver disorders. The medicinal use of lichens can be traced back to the 18th dynasty (1700-1800 BC) when *Evernia furfuracea* was first used as a drug (Lauert, 1981). Herbal medicinal texts included account of several species of lichen including *Cladonia*, *Evernia*, *Lobaria*, *Parmelia*, *Peltigera*, *Pertusaria*, *Physcia*, *Rocella*, *Usnea* and *Xanthoria* (Perez - Llano, 1944). Many such lichens have been scientifically evaluated for various therapeutic activities such as antimicrobial, anti-tumor, antioxidant, immunomodulatory, tyrosinase-inhibitory etc (Malhotra *et al.*, 2008). Hepatoprotective activity of the lichen *Usnea ghattensis* has been established *in vitro* (Verma *et al.*, 2008). Though *P. perlata* has been reported to possess therapeutic activities such as antioxidant, antimicrobial etc, there exist no scientific evidence on its *in vivo* hepatoprotective activity. Thus, in the present work, aqueous slurry of the lichen *P. perlata* was evaluated as an alternative cure on CCl₄ induced hepatotoxicity in rats. The quality of *P. perlata* was found to be as per the prescribed limits in API for parameters like foreign matter, total ash, acid insoluble ash, alcohol soluble extractive and water soluble extractive. The safety of the drug was established by acute oral toxicity study carried out on rats at 2.0 g/kg body weight. The lichen was found to be safe as it showed no abnormal fluctuation in body weights and food and water intake of the animals. Clinical symptoms of toxicity were also found to be absent during the period of the study and no mortality was recorded. The safety study of the lichen revealed that the in form of aqueous slurry, it can be considered safe with a wide margin for oral use. CCl₄ induced hepatotoxicity has been chosen as the experimental model since the changes associated with the CCl₄ induced liver damage are similar to those of viral hepatitis (Contran *et al.*, 1994).

Carbon tetrachloride is commonly used for inducing liver damage because it causes peroxidative degeneration in adipose tissue and is metabolized to trichloromethyl radical and trichloromethyl peroxy radicals which are involved in pathogenesis of liver (Frank *et al.*, 2012; Recknagel, 1983). CCl₄ metabolites react with polyunsaturated fatty acids and form covalent adducts with lipids and proteins. These events lead to lipid peroxidation and destruction of cell membranes with the consequent liver injury (Clawson, 1989; Recknagel *et al.*, 1989). Hepatic damage induced by CCl₄ results in an increase in the level of biochemical parameters like SGOT, SGPT, TG, CHO and TB (Rubea *et al.*, 2011; Frank *et al.*, 2012; Shailajan *et al.*, 2005; 2007). CCl₄ induction also causes classical fatty liver as indicated by significant increase in cholesterol. Group II showed marked increase in all biochemical parameters analyzed and showed severe loss of hepatic architecture with intense peripheral and central vein necrosis, fatty changes and crowding of the central vein

histopathologically [Fig 1(b)]. The established standard drug silymarin was used as modern control. Group IV animals were treated with Silymarin, at a dose of 0.07 g/kg. Silymarin treated rats showed marked recovery in biochemical parameters (SGOT, SGPT, TB, CHO and TG) and offered percentage protection of 64.74%, 58.42 %, 87.92%, 90.04% and 83.58% respectively. Histopathological findings supported the biochemical data as the treated animals showed near normal hepatic architecture with mild degree of necrosis that signifies recovery and protective effect of the drug [Fig 1(d)].

Animals from the groups V and VI were treated with aqueous slurry of *P. perlata* orally at doses of 0.7 g/kg and 1.0 g/kg respectively. The percentage protection offered by the slurry in terms of the reduction in the level of SGOT, SGPT, TB, CHO and TG levels was found to be 37.27%, 44.56%, 75.83%, 77.00% and 66.04% 0.7 g/kg and 53.38%, 64.79%, 106.61%, 99.45% and 72.10% at 1.0 g/kg. The histopathological results also showed marked recovery in the hepatic architecture and reduction in liver damage and cellular necrosis. *P. perlata* slurry at higher dose showed better results in terms of percent protection and histological findings when compared with the lower dose [Fig 1 (e and f)].

Reduction in food and water consumption coupled with the decrease in body weight after CCl₄ treatment indicates toxic response, whereas any significant increase observed in these parameters after plant treatment indicates its protective action. Elevated levels were observed in the CCl₄ induction group as per the results obtained from biochemical parameters (Table 1), which indicate CCl₄ induced damage to the liver. The significant reductions in the levels of SGPT, SGOT, BIL, CHO and TG in case of Silymarin control and in the groups treated with the aqueous slurry of *P. perlata* suggest possible stabilization of the plasma membrane and the repair and recovery of hepatic tissue damage caused by CCl₄ intoxication (Thabrew *et al.*, 1987). This may also imply that the serum levels of transaminases return to normal with the healing of hepatic parenchyma and the regeneration of hepatocytes (Anusha *et al.*, 2011) All the groups except group III (Natural recovery) were sacrificed on day 4. Group III was sacrificed on 7th day of the study. Percent reduction in biochemical parameters (SGOT, SGPT, BIL, CHO and TG) was found to be 20.59%, 15.40%, 43.96%, 52.82% and 6.28% respectively.

Liver sections of the animals in this group showed similar results as to induction group [Fig 1(c)]. From the observations of recovery group, it can be interpreted that as animals did not show significant reduction in biochemical parameters even after the extended recovery period of 7 days, the recovery rate is enhanced significantly by the administration of silymarin and *P. perlata*. Thus, the present study compares the activity of aqueous slurry of *P. perlata* at 0.7 g/kg and 1.0 g/kg with the established drug silymarin in CCl₄ intoxicated rats. The results confer that *P. perlata* shows hepatoprotective activity in a dose dependant manner and the protection shown by the aqueous slurry is at par with that of Silymarin.

Table. 1: Biochemical estimation from serum: All values are Mean \pm SEM.

Groups	Parameters	SGOT	SGPT	Bilirubin (X 10)	Cholesterol	Triglycerides
Normal Control (4 th day)		33.13 \pm 1.39	29.07 \pm 1.89	53.00 \pm 2.31	49.48 \pm 1.71	73.96 \pm 2.65
CCl ₄ control (4 th day)		83.80 \pm 1.67***	76.94 \pm 2.37***	83.33 \pm 3.18***	125.55 \pm 2.80***	126.23 \pm 5.12***
CCl ₄ recovery (7 th day)		73.37 \pm 1.76***	69.57 \pm 2.22***	70.00 \pm 2.08***	85.37 \pm 3.34***	122.95 \pm 3.46***
Percent protection		20.59%	15.40%	43.96%	52.82%	6.28%
Silymarin (4 th day)		51.00 \pm 2.31***	48.98 \pm 2.65***	56.67 \pm 1.46	57.06 \pm 1.95	82.54 \pm 3.81
% protection		64.74%	58.42%	87.92%	90.04%	83.58%
<i>P. perlata</i> (0.7 g/Kg BW) (4 th day)		64.92 \pm 1.43***	55.61 \pm 1.48***	60.33 \pm 1.84	66.98 \pm 3.24*	91.71 \pm 2.91**
Percent protection		37.27%	44.56%	75.83%	77.00%	66.04%
<i>P. perlata</i> (1.0 g/Kg BW) (4 th day)		55.74 \pm 2.38***	45.92 \pm 1.82***	51.00 \pm 2.08	49.90 \pm 2.01*	88.54 \pm 2.47
Percent protection		55.38%	64.79%	106.61%	99.45%	72.10%

*, **, *** represented P = 0.05%, 0.005% and 0.001% level of significance respectively.

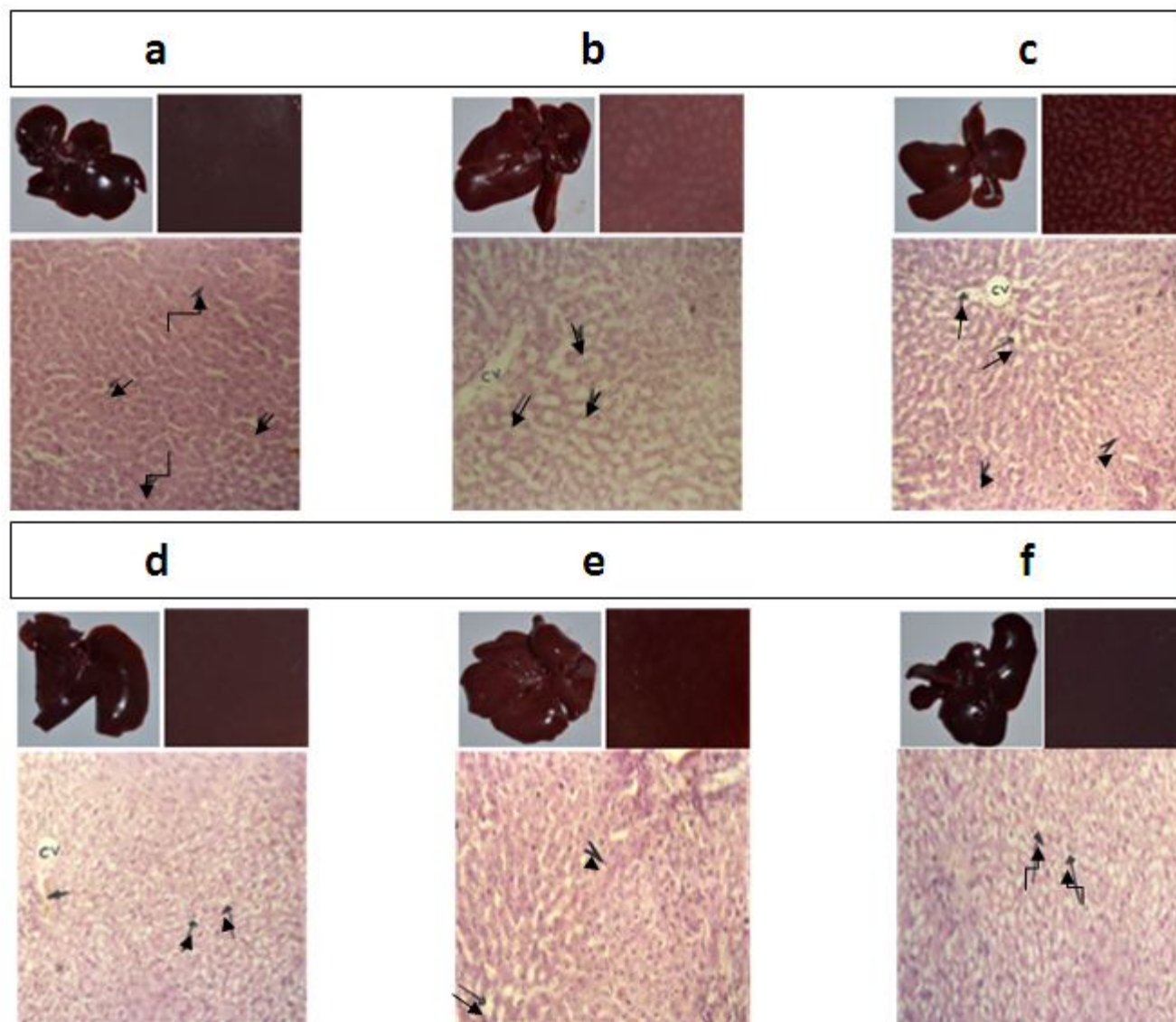


Fig. 1: Histopathology of liver sections (stained with haematoxylin & eosin) from animals of different groups (Magnification X 100). (a): Normal Control – Liver section of control animal demonstrating normal structure, (b): Induction Control – Liver in CCl₄ intoxicated animal, (c): Natural Recovery – Liver in CCl₄ intoxicated animal after a natural recovery period of 7 days, (d): Modern Control – Liver in CCl₄ intoxicated animals treated daily with 0.07 g/kg silymarin, (e): *P. perlata* 0.7 g/kg – Liver in CCl₄ intoxicated animals treated daily with 0.7 g/kg *P. perlata*, (f): *P. perlata* 1.0 g/kg – Liver in CCl₄ intoxicated animals treated daily with 1.0 g/kg *P. perlata*.

CV – Central vein,

Arrows (\rightarrow) – dilated sinusoids,

Arrow heads (\blacktriangleright) – vacuolated hepatocytes,

Bent arrows (\curvearrowright) – hepatocytes.

CONCLUSION

Findings of the present investigation adequately prove the hepatoprotective potential of *Parmelia perlata*. The therapeutic potential shown by *P. perlata* in the management of hepatic dysfunction may be due to its phytochemical constituents acting synergistically. Extraction, isolation and characterization of the constituents responsible for the therapeutic efficacy of *P. perlata* followed by evaluation of their pharmacological action against liver damage can be carried out to identify an even efficient hepatoprotective drug.

ACKNOWLEDGMENTS

The authors wish to acknowledge Avinash Gangurde and Subrath Jana (students of Department of Botany, Ramnarain Ruia College) for arranging the required lichen sample.

REFERENCES

- Adefolaju GA, Ajao MS, Olatunji LA, Enaibe BU, Musa MG. Hepatoprotective Effect of Aqueous Extract of Water Leaf (*Talinum Triangulare*) on Carbon tetrachloride (CCl₄) Induced Liver Damage in Wistar Rats. The Internet Journal of Pathology, 2009; 8 (1). DOI: 10.5580/1c4b
- Anusha M, Venkateswarlu M, Prabhakaran V, Shareen Taj S, Pushpa Kumari B, Ranganayakulu D. Hepatoprotective activity of aqueous extract of *Portulaca oleracea* in combination with lycopene in rats. Indian Journal of Pharmacology, 2011; 43(5): 563–567.
- Chen P, Li C, Pang W, Zhao Y, Dong W, Wang S, Zhang J. The Protective Role of Per2 against Carbon Tetrachloride-Induced Hepatotoxicity. Am J Pathol, 2009; 174(1): 63-70.
- Contran RS, Kumar V, Robbins SL. 1994. Pathologic Basis of Diseases. 5th ed. USA (Philadelphia): WB Saunder Company; 178–89.
- Esimone CO, Ofokansi KC, Adikwu MU, Ibezim EC, Abonyi DO, Odaibo GN, Olaleye DO. In vitro evaluation of the antiviral activity of extracts from the lichen *Parmelia perlata* (L.) Ach. against three RNA viruses. J Infect Developing Countries, 2007; 1(3):315-320.
- Frank PR, Suresh V, Arunachalam G, Kanthlal SK, Ziaudheen VM. Evaluation of hepatoprotective effect of *Adiantum incisum* Forsk. Leaf extract against CCl₄ induced hepatotoxicity in rats. International Research Journal of Pharmacy, 2012; 3(3): 230-234.
- Ganga Rao B, Venkateswara Rao Y, Mallikarjuna Rao T. Hepatoprotective activity of *Spillanthes acmella* Extracts against CCl₄-induced liver toxicity in rats. Asian Pacific Journal of Tropical Disease, 2012; 208-211.
- Halama P, Haluwin CV. Antifungal activity of Lichen extracts and Lichenic acids. A Journal of Biocontrol, 2004; 49(1): 95-107.
- Koh PH, Mokhtar RA, Iqbal M. *Andrographis paniculata* ameliorates carbon tetrachloride (CCl₄)-dependent hepatic damage and toxicity: diminution of oxidative stress. Redox Report, 2011; 16(3):134-43.
- Malhotra S, Subban R, Singh A. Lichens- Role in Traditional Medicine and Drug Discovery. The Internet Journal of Alternative Medicine, 2008; 5 (2): DOI: 10.5580/3d9
- Nayak Y, Abhilash D, Vijaynarayana K, Fernandes J. Antioxidant and hepatoprotective activity of *Pimenta dioica* leaves extract. Journal of Cell and Tissue Research, 2008; 8(3): 1571-1576.
- Patil SB, Ghadyale VA, Taklikar SS, Kulkarni CR, Arvindekar AU. Insulin secretagogue, alpha-glucosidase and antioxidant activity of some selected spices in streptozotocin-induced diabetic rats. Plant Foods Hum Nutr, 2011; 66(1): 85-90. doi: 10.1007.
- Perez- Llano GA. 1944. Economic uses of lichens. Economic Botany, 2:15-45.
- Ramesh KR. Gupta, Rajnish KR. Singh, Nitin KR. Screening of Anti-Hepatotoxic potential of *Solanum xanthocarpum* leaf extract against CCl₄ induced acute hepatopathy in experimental rodents. Asian Journal of Pharmaceutical and Clinical Research, 2012. 5(4), 211-214.
- Recknagel RO, Glende EA Jr, Dolak JA, Waller RL. Mechanisms of carbon tetrachloride toxicity. Pharmacol Ther, 1989; 43: 139-154.
- Recknagel RO. CCl₄ hepatotoxicity status and future prospects. Pharmacol Sci, 1983; 129-131.
- Roy S, Sannigrahi S, Majumdar S, Ghosh B, Sarkar B. Resveratrol Regulates Antioxidant Status, Inhibits Cytokine Expression and Restricts Apoptosis in Carbon Tetrachloride Induced Rat Hepatic Injury. Oxidative Medicine and Cellular Longevity, 2011; 1-12.
- Samal PK. Hepatoprotective activity of *Ardisia solanacea* in CCl₄ induced Hepatotoxic albino rats. Asian Journal of Research in Pharmaceutical Sciences, 2013; 3(2): 79-82
- Shailajan S, Chandra N, Sane RT, Menon S. Effect of *Asteracantha longifolia* Ness. against galactosamine induced liver dysfunction in rats. Toxicol Int, 2007; 14 (1), 07-13.
- Shailajan S, Chandra N, Sane RT, Menon SS. Effect of *Asteracantha longifolia* Ness. against CCl₄ induced liver dysfunction in rats. Indian journal of experimental Biology, 2005; 43: 68-75.
- Silymarin Clinical Update, Profile on the liver herb, (Scientific Communications International Limited, Hongkong), 1995.
- Subramoniam A, Pushpangadan P. Development of phytomedicines for liver diseases. Indian Journal of Pharmacology, 1999; 31: 166-175.
- Tay T, Ozdemir TA, Yilmaz M, Turk H, Kivane M. Evaluation of the antimicrobial activity of the acetone extract of the Lichen *Ramalina farinacea*. Anadolu University, Turkey, 2004; 384-388.
- Thabrew MI, Joice PDTM, Rajatissa WA. Comparative study of the efficacy of *paetta indica* and *Osbeckia octandra* in the treatment of liver disfunction. Planta Medica, 1987; 53: 239-241.
- Thippeswamy B, Sushma NR, Naveenkumar KJ. Antimicrobial property of bioactive factor isolated from *Parmelia perlata*. International Multidisciplinary Research Journal, 2012; 2(2): 01-05.
- Verma N, Behera BC, Makhija U. Antioxidant and hepatoprotective activity of a lichen *Usnea ghattensis* in vitro. Applied Biochemistry Biotechnology, 2008; 151(2-3):167-81.

How to cite this article:

Sunita Shailajan, Mayuresh Joshi, Bhavesh Tiwari. Hepatoprotective activity of *Parmelia perlata* (Huds.) Ach. against CCl₄ induced liver toxicity in Albino Wistar rats. J App Pharm Sci, 2014; 4 (02): 070-074.