



ISSN: 2231-3354
 Received: 16-06-2011
 Revised on: 29-06-2011
 Accepted: 01-07-2011

Cardioprotective, antioxidant activities and Phytochemical analysis by GC-MS of *Gmelina arborea* (GA) in Doxorubicin-induced myocardial necrosis in *Albino* rats

T.Vijay, M.S. Dhana Rajan, K.Sarumathy, S.Palani and K. Sakthivel

T.Vijay

^aResearch and development centre, Bharathiar university, Coimbatore, India

^bP.G & Research Dept. of Biochemistry, KMG College of Arts & Science, Gudiyattam Vellore dist., Nadu, India

M.S. Dhana Rajan

P.G & Research Dept. of Biochemistry, Jaya college of Arts & Science, Tiruninravur, Chennai, India.

K.Sarumathy

^aResearch and development centre, Bharathiar university, Coimbatore, India

^bP.G & Research Dept. of Biochemistry, DKM College for Women, Vellore, India

S.Palani

Dept of Biotechnology, Anna Bioresearch Foundation, Arunai Engineering College, Tiruvannamalai, India.

K. Sakthivel

PG Research, Dept of Zoology, CA Abdul Hakeem College, Melvisharam, Tamil Nadu, India.

*For Correspondence:

T.Vijay,
 Assistant Professor,
 PG & Research Department of Biochemistry
 K.M.G College of Arts & Science,
 Gudiyattam-635 803, Tamilnadu,
 India.
 Mail: vijayamathy@gmail.com

ABSTRACT

Doxorubicin (DOX) is a widely used cancer chemotherapeutic agent. However, it generates free oxygen radicals that result in serious dose-limiting cardiotoxicity. Supplementations with *Gmelina arborea* (*Verbenaceae*) were proven effective in reducing oxidative stress associated with several ailments. The aim of the current study was to investigate the potential protective effect of *Gmelina arborea* (GA) against DOX-induced cardiotoxicity in rats. GA was given orally to rats (250 & 500 mg/kg) and DOX (20 mg/kg) was administered on the seventh day. GA protected against DOX-induced increased levels of marker enzymes. It significantly inhibited DOX-provoked glutathione (GSH) depletion in cardiac tissues. The reductions of cardiac activities of catalase (CAT), superoxide dismutase (SOD), glutathione peroxidase (GSH-Px) and glutathione reductase (GR) were significantly mitigated. Pretreatment of GA significantly guarded against DOX-induced rise of serum lactate dehydrogenase (LDH). GA alleviated histopathological changes in rats' hearts treated with DOX. In conclusion, GA protects against DOX-induced cardiotoxicity in rats. The study can be attributed, at least in part, to GA's antioxidant activity.

Key words: Cardiotoxicity, Doxorubicin, antioxidant, *Gmelina arborea*, histopathological changes.

INTRODUCTION

Doxorubicin (DOX) is an anthracycline antibiotic that is widely used as a chemotherapeutic agent. However, the administration of DOX is known to induce numerous cardiotoxic effects, including transient arrhythmias, nonspecific electrocardiographic abnormalities, pericarditis, and acute heart failure (Billingham et al, 1978 and Bristow et al, 1978). DOX can also cause congestive heart failure months or years after treatment. The mechanism of DOX-induced cardiac injury has been actively investigated, and several hypotheses have been suggested to explain the acute and chronic cardiotoxicity of DOX. Myocardial infarction (MI) is an acute condition of necrosis of the myocardium that occurs as a result of imbalance between coronary blood supply and myocardial demand (De Bono and Boon, 1992). DOX-induced cardiotoxicity in rat was associated with increased lipid peroxide levels in the myocardium (Myers et al., 1977).

A number of herbs are traditionally used in different countries during drug or toxin induced hepatic, renal and cardiac disorders (El-Beshbishy HA, 2005). *Gmelina arborea* (*Verbenaceae*) is herbaceous medicinal plant that has been distributed in Kanniyakumari district, Tamilnadu, India (Chelladurai, 1972). The root and bark of *Gmelina arborea* are useful in treating hallucinations, piles, abdominal pains, burning sensation, fever and urinary discharges. Literature reveals this plant is recommended in combination with other drugs for the treatment of

snake bite and scorpion sting (Dorman et al., 2000). Anti microbial and antioxidative activities of methanol and chloroform extracts of *Gmelina arborea* (GA) are investigated. The antimicrobial activities were determined by using disk diffusion assay and Minimal Inhibitory Concentration (MIC) values. The antioxidant activities are determined by using inhibition of 2, 2 diphenyl picryl - 1- hydrazyl (DPPH) radical and β -carotin / lanoleic acid assay.(Amrutha et al, 2010). It is used as CNS depressant (Yoganarasiman and Chelladurai, 1997) , hypotension and antidiuretic agent (Chopra ,1992). Extensive phytochemical investigations carried out on GA revealed the presence of many chemical constituents including palmitic and linoleic acid such as n-Hexadecanoic acid , 9,12-Octadecatrienoic acid (Z,Z,Z)-, and oleic acid, which are considered significant for Hypocholesterolemic property (Kurian et al, 2005, Hyo Ku Lee et al, 2005, and Hajji Mohamed et al, 2009). All these factors and lack of scientific data on the cardiac activities led to the investigation of the cardioprotective potential of GA, ethanolic extract in rat models. Therefore, the present study was designed to investigate the effects of GA on DOX-induced myocardial necrosis in rats.

MATERIALS AND METHODS

Preparation of *Gmelina arborea* extract

Leaves of *Gmelina arborea* was collected and identified and authenticated (KMGC 12/2010) by V.Chelladurai (Research Officer) Botany (C.C.R.A.S) Government of India. Voucher specimen (KMGC-02/2010-2011) has been retained in the Dept of Biochemistry , KMG College of Arts & Science , Gudiyattam. Materials were cleaned with water and dried in the shade until a constant weight was obtained. It was extracted with 95% ethanol in a Soxhlet extractor. Extracts were concentrated; the percentage yield for ethanol extract was 7.9% and for pharmacological studies, since the ethanol extract was not soluble in water, it is suspended in 5% gum acacia.

GC-MS analysis of ethanol extract of GA for the identification of chemical composition

The identification of chemical composition of ethanol extract of GA was performed using a GC-MS spectrograph (Agilent 6890/Hewlett-Packard 5975) fitted with electron impact (EI) mode. The ethanol extract (2.0 mL) of GU was injected with a Hamilton syringe to the GC-MS manually for total ion chromatographic analysis in split mode. In quantitative analysis, selected ion monitoring (SIM) mode was employed during the GC MS analysis. SIM plot of the ion current resulting from very small mass range with only compounds of the selected mass were detected and plotted.

Induction of experimental myocardial infarction

Doxorubicin was dissolved in sterile double distilled water and injected subcutaneously to rats (20 kg/kg) after last dose of the extract to induce experimental MI (Singh et al, 2008).

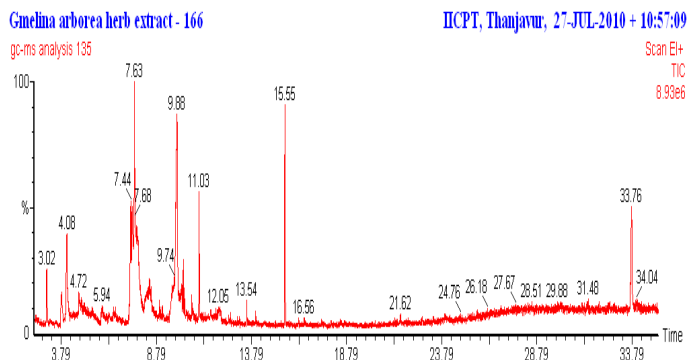


Fig:1 GC-MS analysis of ethanolic GA leaf extract, The chromatogram showing D-Galactose, 6-deoxy- [Synonyms: D-Fucose] (31.28), 7-Azaindole-3-carboxaldehyde (23.87), 1,3-Dimethoxy-5-(1-methyl-heptyl)-benzene (11.52), Phytol and Benzoic Acid (9.47) peaks detected by GC-MS.

Experimental animals

Studies were carried out using Wistar albino rats (150–200 g), obtained from Indian Veterinary Preventive Medicine (IVPM), Ranipet, Tamilnadu, India. The animals were housed in polyacrylic cages (38 cm, 23 cm, 10 cm) and maintained under standard laboratory conditions (temperature 25-20°C) with dark/light cycle (12/12 h). The animals were fed with standard pellet diet (supplied by poultry research station, Nandhanam, India) and fresh water *ad libitum*. All the animals were acclimatized to lab conditions for a week before commencement of the experiment. All the procedures described were reviewed and approved by the University Animals Ethical Committee.

Experimental procedure

- Group 1.(Normal). Saline (0.75 ml/animal), orally for 14 days.
- Group 2.(drug control). Saline (0.75 ml/animal) + DOX 20 mg/kg, single intraperitoneal injection after 14th day.
- Group 3.(Extract control). GA (500 mg/kg), orally for 14 days.
- Group 4.GA(250 mg/kg), orally for 14 days + DOX (20 mg/kg) single intraperitoneal injection after 14th day
- Group 5.GA (500 mg/kg), orally for 14 days + DOX (20 mg/kg) single intraperitoneal injection after 14th day

Isolation of working heart preparation

The animals were anesthetized with chloroform after 72 h of DOX administration, and then heart was punctured with sterile syringe and blood was stored with EDTA which is an anticoagulant agent and was excised out. Cardiac muscle from lower third of the ventricle was visualized under light microscope and the remaining heart tissue was snap frozen in liquid nitrogen.

Histopathological studies

Since it has been ascertained that DOX-induced myocardial lesions are focal and uniformly scattered throughout the whole organ, isolated trial preparation were used instead of the whole heart owing to the greater stability of response and reproducibility of the results. The hearts were removed, washed immediately with saline and then fixed in 10% buffered formalin. The hearts stored in 10% buffered formalin were embedded in paraffin, sections cut at 5 mm and stained with hematoxylin and

eosin. These sections were then examined under a light microscope for histoarchitectural changes.

Biochemical analysis

Blood sample were collected into tubes pre-coated with EDTA by vein puncture at baseline and post intervention. Samples were prepared by centrifuging for 10min 3000×g at 4 °C. Plasma, buffy coat and red blood cell sub-fractions were collected and stored at -80 °C until further analysis. The serum used for the assay of marker enzymes as well as urea, uric acid, was estimated by the methods of (Caraway et al, 1963) and respectively. The activities of serum glutamate-pyruvate transaminase (SGPT) and serum glutamate oxaloacetate transaminase (SGOT) in serum were determined spectrophotometrically by the method of (Mohun and Cook, 1957). The Lactate Dehydrogenase (LDH) and Creatine Phosphokinase (CPK) were determined by the method of (King, 1965) and by the method of (Okinaka, Kumogai, and Ebashi, 1961), respectively. The levels of total cholesterol and triglycerides (TGs) were estimated by the methods of (Zlatkis, Zak and Boyle, 1953, Foster and Dunn, R.T. 1973). Serum high density lipoprotein (HDL) was determined according to the method of (Wilson and Spiger, 1973). Serum low density lipoproteins (LDL) and very low density lipoproteins (VLDL) were calculated as $VLDL = \text{triglycerides}/5$ and $LDL = \text{total cholesterol} - (\text{HDL cholesterol} + \text{VLDL cholesterol})$ respectively. The heart was dissected, immediately washed in ice-cold saline and a homogenate was prepared in 0.1 M Tris-HCl buffer (pH 7.4). The homogenate was centrifuged and the supernatant was used for the assay of antioxidant parameters. MDA content was measured according to an earlier method (Zhang, 1992). Superoxide dismutase (SOD) activity was determined according to (Rai et al, 2006). CAT activity was determined from the rate of decomposition of H_2O_2 according to (Bergmeyer et al,1974). Glutathione peroxidase (GSH-Px) activity was determined by measuring the decrease in GSH content after incubating the sample in the presence of H_2O_2 and NaN_3 according to (Hafemann et al, 1974). GSH reductase activity was assayed according to (Carlberg and Mannervik, 1975) and (Mohandas et al, 1984). GR activity was determined according to the method described by (Staal et al, 1969).

Statistical analysis

The obtained results were analyzed for statistical significance using one way ANOVA followed by Dunnet test statistical software for comparison with control group and DOX treated group. $P < 0.05$ was considered as significant.

RESULTS

i)Effect of basic biochemical parameters on DOX induced cardiotoxicity in rats

Serum urea and uric acid concentrations were significantly increased in the DOX treated animals (Group II) compared to the normal animals(Group I) indicating the induction of severe cardiotoxicity . Treatment with the ethanol extract (250 & 500 mg/kg) of GA showed significant (Group IV & V) decrease in concentrations of serum urea and uric acid compared to the DOX treated group. However the levels of proteins

significantly decreased in the DOX treated groups (Group II), when compared to the control group. Treatment with ethanol extract(250 & 500 mg/kg) of GA significantly (Group IV & V) increased the protein levels, compared to the DOX treated group. There is no significant changes observed in the normal and extract control group (Group IV & V).

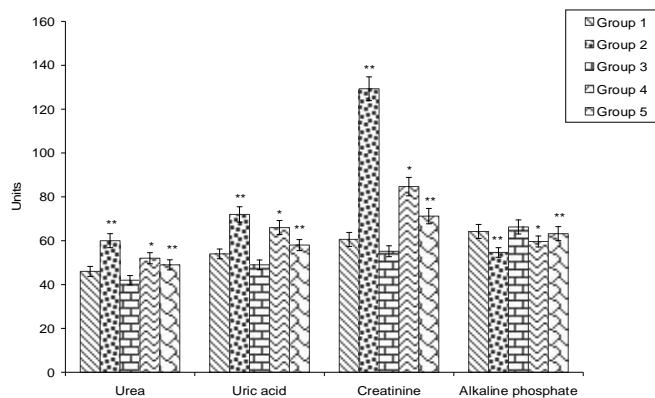


Fig 2: Effect of ethanolic extract GA on Urea (mg/dl), Uric acid (mg/dl), GR (nmol of NADPH oxidized/min/100mg protein), and Alkaline phosphate (mg/dl) in DOX intoxicated rats. Values are near \pm S.D (n=6) ** $P < 0.01$, * $P < 0.05$ respectively.

ii)Effect of Antioxidants on DOX induced cardiotoxicity in rats

Administration of DOX(20mg/kg) to rats significantly reduce the levels of antioxidants such as CAT, SOD, GSH, GPx and the levels of myocardial SOD, CAT, GSH, GPx are increased significantly in ethanol extract of GA treated groups(Group IV & V) when compared with drug control(Group II). Meanwhile, the activities of SOD in the combined GA+DOX groups(Group IV & V) were significantly elevated almost to the control values. Further, GSH and GPx activity was elevated in the combined GA+DOX group. However, it was significantly lower than that of the control group.

iii)Effect of Marker enzymes on DOX induced cardiotoxicity in rats

The serum markers indicating myocardial injury; SGOT and SGPT were significantly elevated in the DOX only treated group(Group II) when compared with the ethanol extract of GA. However, Alkaline Phosphatase(ALP) decreased significantly in the DOX only treated group(Group II) when compared with the ethanol extract of GA. There is a significant increase of ALP in extract control when compared with the drug control group(Group II).But, significant decrease of SGOT and SGPT were observed in extract control (Group IV & V)when compared with drug control group.

iv)Effect of lipid profile on DOX induced cardiotoxicity in rats

There was a significant increase in the concentration of total cholesterol, TG, LDL-C and VLDL-C and significant decrease of HDL-C in blood serum of DOX induced rat when compared to normal untreated rats(Group I).There is no alteration observed in total cholesterol, TG, HDL-C, VDL-C and VLDL-C in the extract control(Group III)when compared with drug control total (Group II).There is a significant decrease of total cholesterol,

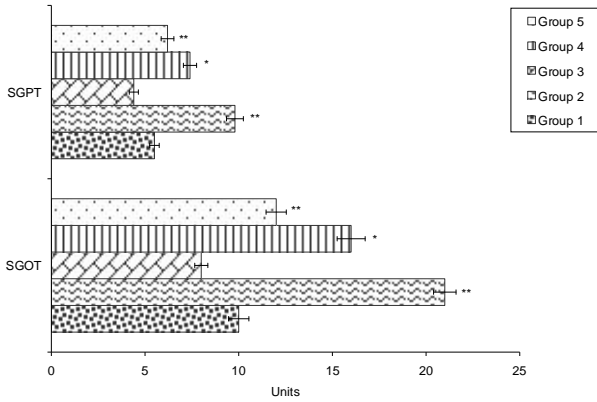


Fig 3: Effect of ethanolic extract GA on SGOT (IU/L) and SGPT (IU/L) in DOX intoxicated rats. Values are near \pm S.D (n=6) **P<0.01, *P<0.05 respectively.

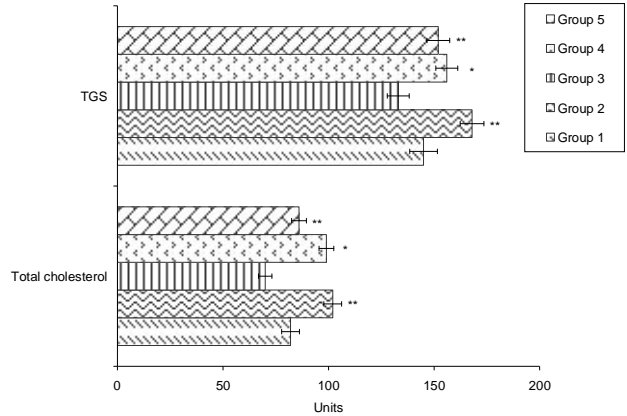


Fig 6: Effect of ethanolic extract GA on serum TGs (mg/dl) and total cholesterol (mg/dl) in DOX intoxicated rats. Values are near \pm S.D (n=6) **P<0.01, *P<0.05 respectively.

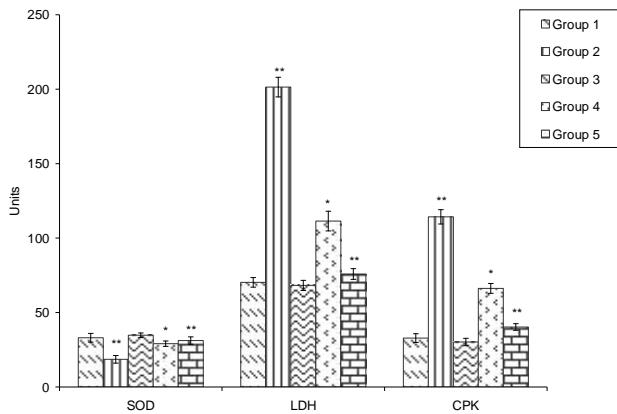


Fig 4: Effect of ethanolic extract GA on SOD (U/mg protein), LDH (IU/L) and CPK (IU/L) in DOX intoxicated rats. Values are near \pm S.D (n=6) **P<0.01, *P<0.05 respectively.

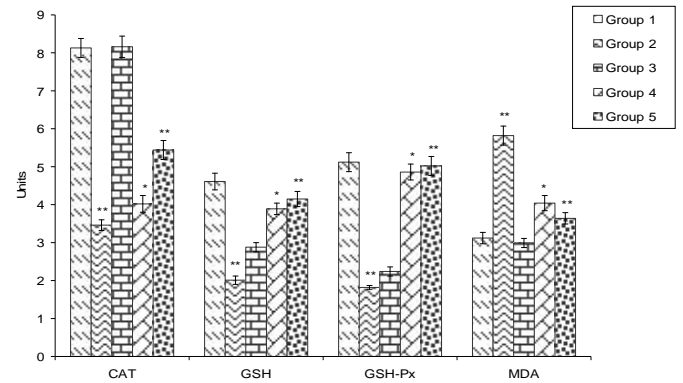


Fig 7: Effect of ethanolic extract GA on CAT (μ mol of H₂O₂ consumed/min/mg protein), GSH (mM/gram tissue), GSH-Px (μ g of GSH oxidized/min/mg protein), and MDA (nmol/g tissue) in DOX intoxicated rats. Values are near \pm S.D (n=6) **P<0.01, *P<0.05 respectively.

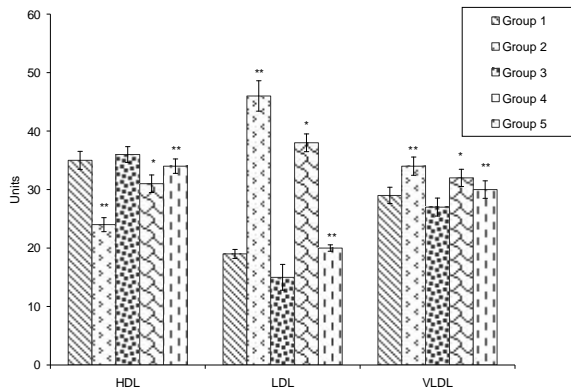


Fig 5: Effect of ethanolic extract GA on serum HDL (mg/dl), LDL (mg/dl), and VLDL (mg/dl) in DOX intoxicated rats. Values are near \pm S.D (n=6) **P<0.01, *P<0.05 respectively.

TG, LDL-C and VLDL-C in the DOX+GA groups(Group IV & V)when compared with normal untreated rat(Group I).

HISTOPATHOLOGY

Histopathological examination of the myocardial of normal rats showed clear integrity of myocardial cell membrane.

Endocardium and pericardium were seen within normal limits. No inflammatory cell infiltration was seen. Rats treated with (20mg/kg) DOX showed moderate to marked myocytic necrosis with moderate infiltration of lymphocytes and macrophages. The changes were pronounced against most of the endocardium and in papillary muscles. Hearts of GA(250mg/kg) treated and DOX challenged rats showed mild to moderate multifocal myocytic necrosis with mild to moderate infiltration of lymphocytes and macrophages. The changes were prominent along most of the ventricular endocardium. GA(Group 500mg/kg)pre- and co-treatment to DOX administered rats, exhibited decreased degree of necrosis(mild) and less infiltration of inflammatory cells. Occasional areas of focal myonecrosis were observed. The treatments of GA(250mg/kg) as well as GA(500mg/kg) to rats showed the heart sections to have histoarchitecture similar to that of normal rats.

DISCUSSION

DOX is an effective and widely used broad spectrum chemotherapeutic agent. However, its clinical use is limited

Table 1 Chemical composition of ethanolic GA leaf extract by GCMS , Activity of Components identified in *Gmelina arborea* herb extract- 166

No.	RT	Name of the compound	Molecular Formula	MW	Peak Area %	Compound Nature	**Activity
1.	3.02	Propane, 1,1-diethoxy-	C ₇ H ₁₆ O ₂	132	3.29	Ether compound	No activity reported
2.	3.81	Glycerin	C ₃ H ₈ O ₃	92	4.12	Alcohol	Antimicrobial Preservative
3.	4.08	Benzoic Acid	C ₇ H ₆ O ₂	122	9.47	Aromatic acid	Antimicrobial Preservative
4.	7.63	7-Azaindole-3-carboxaldehyde	C ₈ H ₆ N ₂ O	146	23.87	Nitrogen compound	Antimicrobial
5.	9.88	D-Galactose, 6-deoxy- [Synonyms: D-Fucose]	C ₆ H ₁₂ O ₅	164	31.28	Sugar compound	No activity reported
6.	10.20	Ar-tumerone	C ₁₅ H ₂₀ O	216	1.65	Ketone compound	Antimicrobial Anticancer
7.	11.03	4-((1E)-3-Hydroxy-1-propenyl)- 2-methoxyphenol	C ₁₀ H ₁₂ O ₃	180	5.35	Phenolic compound	Antioxidant Antimicrobial
8.	15.55	Phytol	C ₂₀ H ₄₀ O	296	9.47	Diterpene	Antimicrobial, Antiinflammatory
9.	33.76	1,3-Dimethoxy-5-(1-methyl- heptyl)-benzene	C ₁₆ H ₂₆ O ₂	250	11.52	Aromatic compound	Anticancer, Diuretic No activity reported

**Source: Dr.Duke's Phytochemical and Ethnobotanical Databases

because of its serious dose dependent cardiotoxicity (Singal and Iliskovic, 1998) clinical and experimental investigations suggested that increased oxidative stress plays a critical role in subsequent cardiomyopathy and heart failure associated with DOX treatment (Siveski-Iliskovic et al, 1985). The present study as designed to investigate the potential protective effect of the ethanolic extract of GA against DOX induced cardio toxicity in rats. *Gmelina arborea* (GA) extract shows antioxidant activity because of its substantial flavanoid content, include flavols and alkaloids (Palani et al, 2009). Flavanoids from some medicinal plants have reduced lipid levels in serum and tissue of rats with induced hyperlipidemia (Anila and Vijayalakshmi, 2002). Our plant, *Gmelina arborea* also has alkaloids, flavonals and flavones (Yoganarasiman and Chelladurai, 1997). Since oxidative stress is a Cornerstone in DOX induced cardiotoxicity (Dbrowska 2008). It was reasonable to investigate the oxidant/antioxidant status of the rats. Current data shows that cardiac levels of oxidized glutathione. Catalysis and protein carbonyl were significantly elevated while those of GSH were significantly reduced following (DOX) administration as compared to control group. The observed GSH deficiency and the rise of the level of GSH caused by DOX might be due to GSH consumption in the interactions of DOX-induced Free radicals with biomembrane and the subsequent lipid peroxidation. Pretreatment of rats with GA significantly guarded against the oxidative stress observed in the DOX group.

Further, the activity of the cardiac antioxidant enzymes CAT, SOD, GSH-Px and GR were significantly reduced while that of HPO was significantly elevated in response to DOX administration as compared to control rats. These data are in accordance with those reported by main investigators (Bleyer, 1990). Our results indicated that GA mitigated decrease of activity of the antioxidant enzymes. Myocardial damage is specific to all anthracycline antibiotics, including myofibrillas degeneration, mitochondrial dilatation, cellular vacuolization and finally myocyte dropout (Nigam, 2007). As seen in the present study, DOX treatment

caused significant histological changes including marked myofibrillar loss and cytoplasmic vacuolization. In rat treated with GA, these DOX induced histological changes were minimal suggesting protection from cellular damage by GA.

The serum enzymes Creatine Kinase cardiac specific proteins serve as sensitive indices to assess the severity of myocardial infarction (Kurian, Philp and Varghese, 2005). In this study, significant decline was shown in the activities of Cardiac markers such as SGOT, SGPT & ALP in the heart of acute DOX treated rats, which is consistent with earlier reports . Decreased activities of these enzymes were due to the leakage from the damaged heart tissues into the blood stream as a result of cardiac problem induced by DOX in rats observed that these Cardio-Specific marker enzymes are released from the heart into the blood during myocardial damage due to myofibril degeneration. Significant increase was noticed in the activities of Cardiac markers (SGOT, SGPT & ALP) in plasma of DOX treated rats, which is consistent with earlier reports (Senthil, Sridevi and Pugalendi, 2007) might be due to enhanced susceptibility of myocardial cell membrane to the isoproterenol mediated Peroxidative damage, resulting in increased release of these diagnostic marker enzymes into the systemic circulation (Mathew et al, 1981).

In the present study, the prior administration of GA significantly prevented the DOX induced elevation in the levels of diagnostic marker enzymes in plasma indicating the Cyto protective activity of GA. Thus, it is possible that likewise GA may also prolong the viability of myocardial cell membrane stabilizing action.

Myocardial infarction (MI) is also associated with altered lipid metabolism. The increased concentration of cholesterol could be due to a decrease in HDL-C. Since HDL-C is known to be involved in the transport of cholesterol from tissues to the liver for its catabolism (Sushamakumari et al, 1990). In this context, we have observed decreased levels of HDL-C in DOX-treated rats.

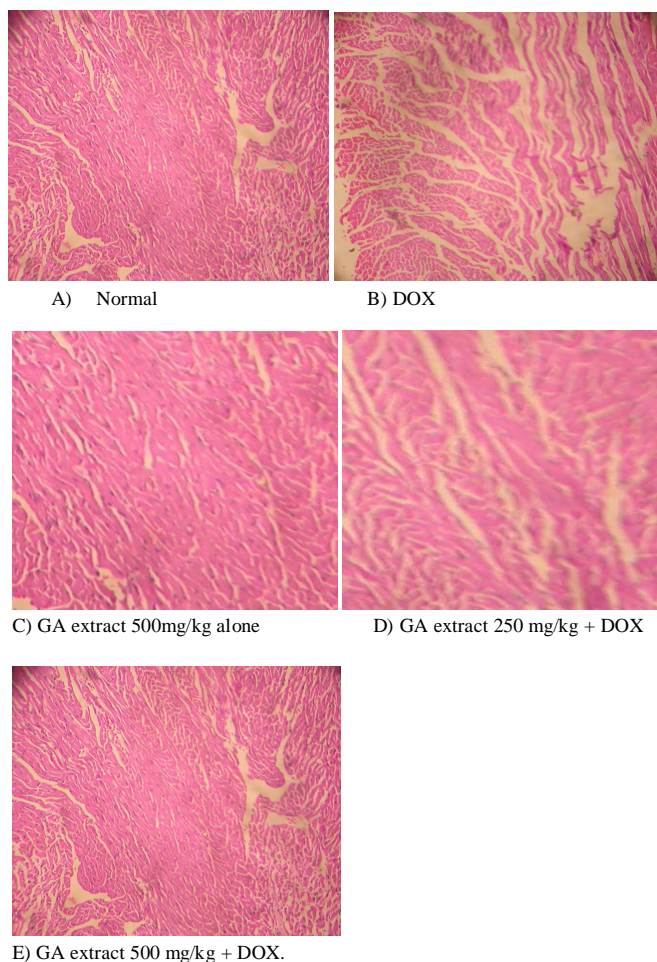


Fig:8 Cardioprotective effect of *Gmelina arborea* ethanolic extract. Histopathological observations (heart sections stained with Hematoxylin-Eosin, magnification-100x) (A) Normal, (B) DOX, (C) GA extract 500mg/kg alone, (D)GA extract 250 mg/kg + DOX, (E)GA extract 500 mg/kg + DOX.

The decreased levels of Phospholipids in DOX-treated rats might be due to the enhanced membrane degradation. Pretreatment with GA decreases the concentration of total cholesterol in heart of DOX-induced rats. In the present study, the levels of serum total cholesterol, LDL-C and VLDL-C were increased while the levels of HDL-C were decreased in DOX-treated rats. Studies have shown that high levels of LDL Cholesterol have a positive correlation with MI, whereas high levels of HDL cholesterol have a negative correlation with MI (Buring et al,1992). Pretreatment with GA decreases the levels of serum total cholesterol, LDL-C, VLDL-C and increases HDL-C in DOX-treated rats.

CONCLUSION

The present study shows that the administration of ethanol extract of GA has cardioprotective potential against DOX-induced cardiotoxicity. It provides experimental evidence that GA augmented the myocardial antioxidant enzymes level, preserved histoarchitecture and improved cardiac performance following DOX administration. This cardioprotective activity of GA might be due to the synergistic effect of chemical compounds

present in them making them good sources for the production of a cardioprotective herbal medicine. The identification of molecules with cardioprotective potential from this ethanol extract of GA may provide new directions for identification of cardioprotectives, which could be given concomitantly during Dox treatment.

ACKNOWLEDGEMENTS

The authors thank the management of K.M.G college of Arts & science for the support rendered by them for the completion of this work. Authors also thank Dr. S.Kumaravel, Senior Scientist, Paddy processing Research Centre, Thanjavur, Tamil Nadu for GC/MS analysis.

REFERENCE

- Amrutha V. Audipudi and Bhaskar V.S. Chakicherla , Antioxidative and Antimicrobial Activity of Methanol and Chloroform Extracts of *Gmelina Arborea* Roxb. Inter. Jour. of Biotech.and Biochem. . 2010; 6(1): 139-144
- Anila, L., Vijayalakshmi, N.R.,.. Flavonoids from *Embolia officinalis* and *Mangifera indica* effectiveness for dyslipidemia. J. Ethnopharmacol. 2002;79 (1): 81-87.
- Bergmeyer, H.U., Gowehn, K and Grassel. H. Enzymes as biochemical reagents. In Methods of Enzymatic Analysis.1974;4:38-39.
- Billingham M.E, Mason J.W, Bristow M.R, Daniels J.R, Anthracycline cardiomyopathy without interfering with its antitumor effect. Circulation,1978;9: 10-15.
- Bristow M.R, Thompson P.D, Martin R.P, Mason J.W, Billingham M.E, Harrison D.C, Early anthracycline cardiotoxicity, Am. J. Med. 1978; 65: 823-832.
- Buring JE, O' Connor GT, Goldhaber SZ, Rosner B, Herbert PN, Blum CB, Decreased HDL2 and HDL3, Cholesterol APO A1 and APO A2 and increased risk of myocardial infarction, Circulation , 1992;85:22 -29.
- Bleyer, W. The impact childhood cancer on the United States and the world. CA Cancer J. Clin. 1990;40: 355-367.
- Caraway, W.T.. In Standard Methods of Clinical Chemistry. 4th ed., Academic Press, London1963;4: 239-247
- Carlberg, I., and Mannervik, B.. Glutathione reductase levels in rat brain. *J Biol. Chemistry*. 1975;250: 5475-5479.
- Chelladurai, V. Glossory of Indian medicinal plants with active principles , CSIR, New Delhi, part I, 1972; 340-341
- Chopra R.N . Glossory of Indian medicinal plants with active principles, CSIR, New Delhi, part II , 1992; 512-513
- Dbrowska, K., Stuss, M., Gromadzin' ska, J., Wasowicz, W., Sewerynek, E., . The effects of melatonin on glutathione peroxidase activity in serum and erythrocytes after adriamycin in normal and pinealectomised rats. *Endokrinol. Pol.* 2008;59 (3), 200-206.
- Dorman HJD. " In vitro evaluation of antioxidant activity activity of essential oils and their components," *Flavour Fragrance J.* 2000;15(1), 12-16
- De Bono, D.P., Boon, N.A. Diseases of the cardiovascular system. In Edwards CRW, Boucheir IAS, editors. David- son's principles and practice and medicine. Hong Kong: Churchill Livingstone. 1992; 249-340.
- El-Beshbishy HA. Hepatoprotective effect of green tea *Camellia sinensis*] extract against tamoxifen-induced liver injury in rats, *J. Biochem. Mol. Biol.* 2005;38, 300-306.
- Foster, L.V., Dunn, R.T. Stable reagents for determination of serum triglycerides by a colorimetric Hatzsch condensation method. *Clin Chem.* 1973;19:338-340.
- Gurvinder Singh., Anu Singh, T., Aji Abrahama., Beena Bhat., Ashok Mukherjee., Ritu Verma., Shiv Agarwal, K., Shivesh Jha ., Rama Mukherjee., Anand Burmana, C. Protective effects of *Terminalia arjuna*

against doxorubicin-induced cardiotoxicity. *J Ethnopharmacology*. 2008;117:123–129.

Hafemann, D.G., Sunde, R.A., and Houestra, W.G. Effect of dietary selenium on erythrocyte and liver glutathione peroxidase in the rat. *J. Nutrition*. 1974;104: 580–4.

Hajji Mohamed , Masmoudi Ons, Ellouz-Triki Yosra, Siala Rayda, Gharsallah Neji, Nasri Moncef.. Chemical composition and antioxidant and radical-scavenging activities of *Periploca laevigata* root bark extracts. *J. Sci Food & Agri* 2009;89(5): 897 – 905.

Hyo Ku Lee., Yang Mun Choi., Dong Ouk Noh and Hyung Joo Suh. Antioxidant Effect of Korean Traditional Lotus Liquor (*Yunyupju*) *Inter. J Food Sci & Tech*. 2005;40 (7):709 -715.

King, J., *In Prac Clini Enzymology*. Van D. ed., Nostrand Co, London1965; 83-93.

Kurian GA, Philp S, Varghese T. Effect of aqueous extract of *Desmodium gangeticum* DC root in the severity of myocardial infarction. *J Ethnopharmacol*; 2005;97:4557-61.

Mathew S, Menon VP, Kurup PA . Changes in myocardial aortic lipids, lipolytic activity and fecal excretion sterol and bile acids in Isopreterenol induced myocardial infarction, *Indian J Biochem Biophys*; 1981; 18:131.

Sushamakumari S, Varghese A, Muraleedharan D, Menon VP. Protective action of Aspirin in experimental myocardial infarction induced by Isopreterenol in rats and its effect on lipid peroxidation , *Indian J Exp Biol*; 1990;28:480. 19 .

Myers, C.E., McGuire, W.P., Liss, R.H., Ifrim, I., Grotzinger, K., Young, R.C. Adriamycin: the role of lipid peroxidation in cardiac toxicity and tumor response. *Science* 1977;19, 165–167.

Mohun, A., Cook, I.J. Simple methods for measuring serum level of glutamic oxaloacetic and glutamic pyruvic transaminases in routine laboratories. *J Clin Pathol*. 1957 ;10: 394-399.

Nigam PK. Biochemical markers of myocardial injury. *Indian J Clin Biochem*. 2007;22:10-17.

Okinaka, S.H., Kumogai, S., Ebashi, S. Activity in Progressive Muscular Dystrophy and Neuromuscular Diseases. *Arch. Neurol*. 1961;4: 520-525.

Mohandas, J., Marshall J.J, Duggin, G.G., Horvath, J.S and Tiller., D. Differential distribution of glutathione and glutathione related enzymes in rabbit kidney: possible interactions in analgesic neuropathy. *Cancer Research* 1984;44: 5086–91.

Palani S, Raja S, Praveen kumar R, Soumya Jayakumar, Senthil kumar B, *International Journal of Pharmtech Research* 2009;Vol.1: 925-934.

Rai, S., A. Wahile, K. Mukherjee, B.P. Saha, and P.K. Mukherjee. Antioxidant activity of *Nelumbo nucifera* (sacred lotus) seeds. *J Ethnopharmacology*. 2006;104: 322–7.

Senthil S, Sridevi M, Pugalendi KV. Protective effect of Ursolic acid against myocardial ischemia induced by isoproterenol in rats. *Toxicol Mechn Methd*; 2007;17:57-65

Staal, G.E., Visser, J., Veeger, C., Purification and properties of glutathione reductase of human erythrocytes. *Biochim. Biophys. Acta*. 1969;185: 39–48.

Singal, P.K., Iliskovic, N. Doxorubicin-induced cardiomyopathy. *N. Engl. J*. 1998;339: 900–905.

Siveski-Iliskovic, N., Hill, M., Chow, D.A., Singal, P.K., Probucol promotes endogenous antioxidants and provides protection against adriamycin-induced cardiomyopathy in rats. *Circulation* 1995;89:2829–2835.

Takemura, G., Fujiwara, H., Doxorubicin-induced cardiomyopathy from Cardiotoxic mechanisms to management. *Prog. Cardiovasc. Dis*. 2007;49: 330–352.

Wilson, D.E., Spiger, M.J. A dual precipitation method for quantitative plasma lipoprotein measurement without ultra-centrifugation. *J Lab Clin Med* , 1973; 82:473.

Yoganarasiman and Chelladurai, *Medicinal plants of India* , 1997;volume-II , 128

Zlatkis, A., Zak, B., Boyle, G.J. A new method for the direct determination of serum cholesterol. *J Clin Med*. 1953; 41: 486-92.

Zhang, X.Z. *Crop physiology research methods*. Beijing: China Agricultural Press 1992 ;1:82-86