

Acute Toxicity study on *Citrullus colocynthis* fruit methanol extract in Albino rats

Soufane S.¹, A. Bedda³, N. Mahdeb⁴, A. Bouzidi²

¹Département de Biologie, Faculté des sciences de la nature et de la vie, Université Elbachir Elbrahimi, 34000 BBA, Algérie.

²Département de Biologie, Faculté des sciences de la nature et de la vie, Université Ferhat Abbas, Sétif 19000, Algérie.

³Département d'environnement, Ecole Nationale polytechnique, El-Harrach, Algier-16000, Algérie.

⁴Département d'agronomie, Université Ferhat Abbas, Sétif 19000 Algérie.

ARTICLE INFO

Article history:

Received on: 15/03/2013

Revised on: 02/04/2013

Accepted on: 01/06/2013

Available online: 27/06/2013

Key words:

Methanol extract, LD₅₀,
Citrullus colocynthis, pulp,
acute toxicity.

ABSTRACT

The fruit of *Citrullus colocynthis* (L.) Schrad. (Cucurbitaceae) in its dried or fresh forms is consumed by some patients of M'sila region (Algeria) for its antidiabetic, antirheumatic, antihaemorrhoids activities without considering its safety. The first step of the study was undertaken to determine the acute median lethal dose of the methanol extract. The objective of the second step was to evaluate the toxic effects of this extract at a single daily oral dose (131mg/kg) in 50 Albino rats divided into 5 experimental (A, B, C, D and E) and 1 control groups after different periods of treatment. Liver, kidney and bone marrow function test were assessed using standard techniques. The acute median lethal dose of the extract was found to be 1311,45 mg/kg. The plasma ALT, AST, urea and creatinine levels were significantly affected, an indication that the extract is hepato-nephrotoxic. The results obtained for hematological parameters reflect that methanol extract with a dose of 131 mg/kg did not affect quantitatively but disrupted qualitatively some functions of the bone marrow. The present study showed that the intake of extract of ripe *Citrullus colocynthis* fruit presented some adverse effects on the functions of the liver, kidney and bone marrow in rats.

INTRODUCTION

The Cucurbitaceae plant, *Citrullus colocynthis* is locally known as "Handhal" or "Hdej", and prevalent in south Algeria. It is also called Wild Watermelon, Bitter apple, Bitter gourd and Bitter cucumber (Zamani *et al.*, 2007). Colocynth (CCT) contains active substances such as saponins, alkaloids and glycosides (Abdel-Hassan *et al.*, 2000). The main constituents of the plant are highly oxygenated tetracyclic triterpene compounds called cucurbitacins (Seger *et al.*, 2005). There are a variety of cucurbitacin compounds including cucurbitacin A, B, C, D, E, F, I, L and glucosides (Nayab *et al.*, 2006). Fruit contains α -glucosides colocynthin, its aglycone α -elaterin, citrullin, citrullene and citrullinic acid. Unripe fruits contain p-hydroxy benzyl ester. Roots contain α -elaterin and hentriacontane (Husain *et al.*, 1992). The *Citrullus colocynthis* is well reputed for its therapeutic activity in folklore. The fruits and, in particular, the pulp of this plant are well known natural cathartics since ancient times.

* Corresponding Author

S. Soufane, Département de Biologie, Faculté des sciences de la nature et de la vie, Université Elbachir Elbrahimi, 34000 BBA, Algeria.

The leaves of this herb are used to treat asthma and jaundice, whereas the root is a traditional treatment for amenorrhea, breast inflammation, arthralgias, and ophthalmic diseases. Other medicinal uses include the treatment of seizures, tuberculosis, syphilis, and parasitic infections (Blaskovich *et al.*, 2003). *C. colocynthis* is mostly used by many diabetics in developing countries (Errajaji *et al.*, 2010; Ziyat *et al.*, 1997). Many scientific studies have been undertaken on laboratory animals to show the hypoglycemic effect of this plant (Khalil *et al.*, 2010; Atole *et al.*, 2009). Case reports associate the use of extracts of *Citrullus colocynthis* with the development of bloody diarrhea, vomiting, colicky abdominal pain, and dehydration (AlFaraj, 1995). Pathologic lesions primarily involve edema, erythema, superficial erosions and inflammatory exudates of the mucosa in the sigmoid and descending colon. Ulcerations and pseudopolyps are unusual features of this toxic colitis. Symptoms typically resolve within 3-6 days, and the pathological lesions resolve within 14 days without sequelae. There are few data on the dose response of the toxin in colocynth, in part because of the lack of identification of the specific compound associated with the toxic colitis.

The older medical literature suggests that 0.6- 1 g of colocynth extract can produce bloody diarrhea (Goldfain *et al.*, 1989). The objective of this study is to evaluate the acute toxicity of the fruit extract of *C. colocynthis* on liver and kidney of male rats Wistar Albino.

MATERIAL AND METHODS

Plant material

Citrullus colocynthis (CCT) plant were collected during August and September from the desert area of Maârif (35,5°W and 5,25°N) in province of Boussaâda, Wilaya of M'sila, Algeria. The plant was identified, authenticated by Botanist Pr. H. Laouer, Department of Biology, Ferhat Abbas University, Setif, Algeria. Fruits were washed and shade dried. Seeds were separated manually from the pulp of the fruits and then minced with electrical grinder (Muleinex) into a powder and finally stored in airtight containers prior to use (Fig. 1, 2).



Fig. 1: Bitter Apple (*Citrullus colocynthis*).



Fig. 2: Fruit of *Citrullus colocynthis* in its dried and fresh forms with cut section.

Preparation of the methanol extract of the fruit of *Citrullus colocynthis*

Hundred grams of Air dried powdered of fruits were extracted to exhaustion with 600 ml methanol, using a soxhlet apparatus for 18 h. The resulting extracts were evaporated at reduced pressure to obtain crude extract. The yield of this extract was approximately 13.73± 0.02% (w/w).

Experimental animals

Male Albino-Wistar rats weighing between 180 to 210 g were obtained from animal center of Pasteur's Institute (Algiers – Algeria). Rats were housed in hanging transparent plastic cages (55 × 33× 19 cm) in the animal room of Faculty of Sciences University Ferhat Abbas Setif Algeria and acclimated for 3 weeks prior to experiment. The litter was renewed every 3 days. They were fed with a standard pellet and tap water *ad libitum*. All animals were kept in standard environmental conditions. Each rat was identified by body marks using 1% picric acid solution. All experimental procedures were conducted in accordance with the guide for care and use of laboratory animals and in accordance with the scientific council of the Faculty of Natural Sciences and Life of the University Ferhat Abbas, Sétif – Algeria.

Acute toxicity studies in male rat.

Determination of LD_{50}

The fruit extract of *Citrullus colocynthis* to be tested is dissolved in a few drops of methanol and diluted in saline and administered at different doses, by gavage at a dose pergroup. Male rats were weighed 186.25 ±2.80 g, identified by labeling with an aqueous solution of picric acid and divided into groups of 10 animals each and fasting for short period before oral administration of single doses of the fruit-extract of *Citrullus colocynthis*. Five groups of rats are treated with simple application and successively with the following doses: 500, 1000, 1800, 2000 and 3000 mg/kg. The control group received physiological saline with a few drops of alcohol. After administration of the extract of fruits, animals were observed individually every hour during the first day and every day for 14 days. Behavior and clinical symptoms of animals are noted throughout the duration of the experiment. LD_{50} and its range are calculated by the graphic method of Litchfield and Wilcoxon (1949).

Acute toxicity in male rats.

The rats were divided in random into 5 groups, each of 10 rats. Four groups received *per os* 131 mg/kg ($\approx 1/10 DL_{50}$) of the methanolic extract of fruit pulp of *Citrullus colocynthis* but were killed after 24 hours, 5 days, 10 days and 14 days of the treatment. One group was maintained as normal control and received normal saline. At the end of all experimental periods, animals were anaesthetized with urethane at the dose 760 mg/kg. Two kinds of blood were obtained from the retro-orbital vein, a sample for hematology containing ethylene diamine tetraacetic acid for measurement (Erythrocyte (RBC) and leukocyte (WBC)

counts, hemoglobin concentration (Hb), mean corpuscular volume (MCV), mean corpuscular hemoglobin (MCH), mean corpuscular hemoglobin concentration (MCHC), mean platelet volume (MPV) and platelets hematocrit (PCT) with apparatus MEDONIC (Beckman Coulter – USA) and sample for serum and used for measurement of activities Glutamic-oxaloacetic transaminase (GOT), Glutamic- Pyruvic Transaminase (GPT) (using commercial Kits –SGM Rome-Italy) , alkaline phosphatase (ALP) (using commercial Kits – CYPRESS DIAGNOSTIC Langdrop – Belgium), concentrations of total protein, urea, glucose, creatinine, sodium, potassium, calcium and phosphorus with apparatus TECHNICON RA-1000-USA. After blood collection, the animals were sacrificed by cervical dislocation. After autopsy, all tissues were examined grossly and major's organs (liver, brain, heart, kidneys, spleen, testes and lung) were weighted. The relative organ weight (weight of organ as a proportion of the total weight of each rat) was calculated and compared with the value of the control

Statistical analysis

The t-test and a probability level of $P < 0.05$ were chosen as the criteria for statistical significance. Values reported are mean \pm standard error of the mean (SEM).The median lethal dose LD₅₀ was determined according to Litchfield and Wilcoxon method (1949).

RESULTS

The Median lethal dose

The animals were kept under observation for 72 hours after dosing to check for symptoms, behavioral changes and death. The doses tested produced, early within the first few hours of treatment the following signs which worsens with the passing of the time: lose of locomotion activity, ataxia, and at the highest doses administered, lethargy, hypothermia and death. Severe diarrhea was the most serious symptoms; after developing it, all the experimental animals died.

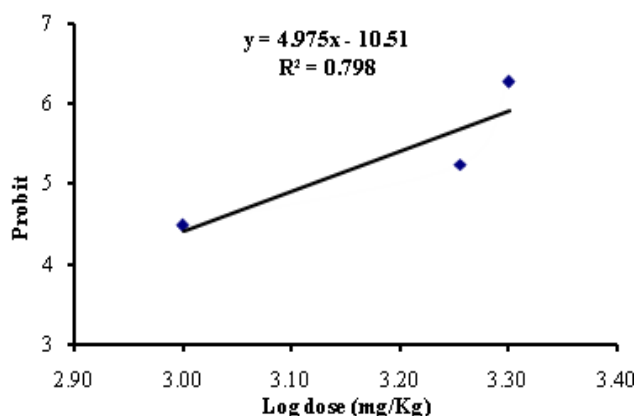


Fig. 3: Median lethal dose (LD₅₀) of the fruit methanolic extract of *C. colocynthis* in male Wistar rats.

The animals that survived had some symptoms, including mild diarrhea, but were able to recover. The intensity of the toxic

effects was dose-dependent. Rats mortality after different doses of CCT methanol extract was plotted against probability values (Litchfield and Wilcoxon, 1949). The mortality rate in male rats was maximum (100%) in groups treated with 3000 mg/kg.

The acute median lethal dose (LD₅₀) of the extract was found to be respectively 1311,45 mg/kg (at 95% confidence limit of (1037,80 to 1657,27 mg/kg) for male rats. The LD₁₆ and LD₈₄ were respectively 825,61 mg/Kg and 2083,19 mg/Kg (Fig. 3).

Acute toxicity in male rats

The main signs of toxicity observed after oral administration of single dose tested (131 mg/kg \approx 1/10 LD₅₀) were: diarrhea, ruffled hair, acceleration of heart rate, breathing difficulty, soft feces and huddling together. None of the rats in all treated groups died during the course of the experiment.

There were no statistically significant differences in average body weight of the control group and *Citrullus colocynthis* fruit-extract treated groups during the acute toxicity. But significant differences were detected in the weight gain of male rats treated C.C fruit extract, as compared to control group (Table. 1). Macroscopic examination of various organs *in situ* did not show any morphological changes in organs of treated animals compared with those of control rats.

No significant changes were noted on the relative weights of liver, brain, kidney and testes among the treated groups. But the group sacrificed after 10 days of treatment has presented a significant reduction in the relative weights of the kidney, lungs, heart and spleen compared to control group (Table 2).

The hematological parameters of rats treated with *Citrullus colocynthis*-extract are presented in table 3. The RBC (red blood cells), HCT (hematocrit), HGB (hemoglobin) and WBC (White blood cells) were higher in the treated groups than control group. The major hematological parameters returned to normal after the 14th days.

The results of the indices of liver function AST (GOT) (glutamic-oxaloacetic transaminase), ALT (GPT) (glutamic-pyruvic) and ALP (alkaline phosphatase) and TP (total protein) are given in table 4. It was observed that the values of GOT and GPT on Day 1 and 5 were significantly higher compared to control. ALP activity was significantly higher in treated groups, sacrificed after 10 and 14 days of application. TP estimation of the acute toxicity revealed significant differences in the most treated groups compared to control (Table-4).

Effect of CC-fruit-extract on kidney function parameters (Table-5) shows the mean kidney function values of the rats treated with CC-fruit-Extract. From the table urea, creatinine and potassium levels were significantly increased in groups A, C, and D when compared with the control.

Calcium was significantly higher in groups A, B and C. no significant variation were obtained in the serum sodium and glucose tested when compared with control.

Table. 1: Effect of acute administration of methanol CCT pulp fruit extract (131 mg/kg) on body weight of male rats .

Group	1 st day	5 th day	10th day	14 th day	Difference
Group 1stday	203,5±7,92				
Group 5thday	178,5±3,25	182,5±5,49			4±5,715*
Group 10thday	196,5±5,11		213±5,88		16,5±6,67
Group 14eenday	199,5±4,25			253±7	56.67±3.77*
Control	199,5±9,17	191±5,06	208,25±4,92	272±10,00	25.00±7.92

Values are Mean±SEM, * Significantly different at P< 0.05.

Table. 2: Relative organ's weight of Albino Wistar male rats treated orally with 131 mg/kg of methanol CCT pulp fruit extract.

Organ	Control	Group A	GroupB	GroupC	GroupD
Liver	0.036 ± 0.0014	0.038 ± 0.001	0.037 ± 0.0011	0.036 ± 0.001	0.035 ± 0.0015
Kidney	0.007 ± 0.0004	0.006 ± 0.0002	0.007 ± 0.0003	0.006 ± 0.0001*	0.007 ± 0.0003
Brain	0.008 ± 0.0002	0.008 ± 0.0003	0.009 ± 0.0002	0.007 ± 0.0003	0.008 ± 0.0003
Testes	0.011 ± 0.0011	0.012 ± 0.0003	0.012 ± 0.0008	0.011 ± 0.0006	0.012 ± 0.0006
Lungs	0.006 ± 0.0002	0.005 ± 0.0003	0.007 ± 0.0005*	0.005 ± 0.0004*	0.0066 ± 0.0002
Heart	0.003 ± 0.0002	0.003 ± 0.0001	0.003 ± 0.0002	0.0025 ± 0.0001*	0.0035 ± 0.0001
Spleen	0.004 ± 0.0004	0.002 ± 0.0001*	0.004 ± 0.0002	0.0024 ± 0.0002*	0.0037 ± 0.0002

Values are Mean±SEM, * Significantly different at P< 0.05.

Table. 3: Hematological changes in rats treated orally with 131 mg/kg of methanol CCT pulp fruit extract.

Parameter	Control	Group A	GroupB	GroupC	GroupD
RBC (10 ¹² /l)	7.98± 0.52	10.05± 0.19*	9.10± 0.18*	8.41± 0.19	8.09± 0.26
WBC (10 ⁹ /l)	7.36± 0.97	16.68± 2.57*	9.64 ± 1.00	11.32± 0.56*	8.37± 0.83
Hb (g/dl)	13.96± 0.61	18.083± 0.45*	15.82 ± 0.25*	15.63± 1.42	14.47± 0.52
HCT (%)	39.74±1.86	49.15±1.18*	44.85± 0.75*	41.49±0.94	40.09±2.52
MCV (f/l)	50.25± 0.86	48.07 ± 0.64	49.31 ± 0.62	48.98 ± 0.61	52.78 ± 0.70*
MCH (pg)	17.55± 0.35	17.78 ± 0.20	17.41± 0.23	19.50± 1.28	17.47 ± 0.17
MCHC (g/dl)	34.92± 0.26	37.04 ± 0.21*	35.31 ± 0.07	40.08± 2.26	33.13 ± 0.26*

Values are Mean±SEM, * Significantly different at P< 0.05.

Table. 4: Effect of methanol CCT pulp fruit extract administration (131 mg/kg) on some liver function tests of Albino Wistar male rats.

Parameter	Control	Group A	GroupB	GroupC	GroupD
Total protein (TP, g/l)	55.00± 1.00	66.00 ± 1.60*	57.20± 0.58	66.67 ± 2.47*	64.87± 1.33*
AST (UI/l)	148.37± 9.87	201.44 ± 16.23*	176.50 ± 11.92 ^{NS}	219.20 ± 17.04*	195.30 ± 15.05*
ALT (UI/l)	43.71± 2.20	70.11± 5.72*	51.43± 1.94*	73.70± 9.94*	53.33± 3.1
ALP (UI/l)	187.89 ± 8.75	179.00 ± 12.01 ^{NS}	208.89± 17.18 ^{NS}	246.70 ± 23.56*	239.70± 12.82*

Values are Mean±SEM, * Significantly different at P< 0.05.

Table. 5: Effect of methanol CCT pulp fruit extract administration (131 mg/kg) on glucose concentration and some renal function tests of Albino Wistar male rats.

Parameter	Control	Group A	Group B	Group C	Group D
Glucose (mg/l)	1.11 ± 0.08	1.40 ± 0.20 ^{NS}	1.19 ± 0.08 ^{NS}	0.99 ± 0.16 ^{NS}	0.91 ± 0.08 ^{NS}
Sodium (mg/l)	127.10 ± 1.40	131.10 ± 3.16 ^{NS}	129.00 ± 2.40 ^{NS}	127.79 ± 8.370 ^{NS}	125.22 ± 2.07 ^{NS}
Potassium (mg/l)	3.68 ± 0.12	4.82 ± 0.11*	3.67 ± 0.14 ^{NS}	5.84 ± 0.25*	5.53 ± 0.18*
Calcium (mg/l)	77.80 ± 0.55	111.30 ± 1.2*	73.00 ± 1.28*	108.22 ± 0.78*	82.23 ± 3.07 ^{NS}
Phosphorus (mg/l)	77.00 ± 3.47	52.44 ± 1.62*	77.00 ± 2.57 ^{NS}	61.40 ± 5.34*	75.96 ± 2.61 ^{NS}
Urea (mg/dl)	21.00 ± 2.00	100.00 ± 11.0*	18.00 ± 0.50 ^{NS}	96.00 ± 15.00*	62.00 ± 3.00*
Creatinine (mg/dl)	52.70 ± 3.50	73.90 ± 3.30*	70.60 ± 8.20 ^{NS}	86.50 ± 13.00*	86.00 ± 10.50*

Values are Mean±SEM, * Significantly different at P< 0.05.

DISCUSSION

Citrullus colocynthis find wide-spread use in folkloric medicine for treatment of various disorders (Nmila *et al.*, 2000; Adam *et al.*, 2001; Tannin-Spitz *et al.*, 2007; Kumar *et al.*, 2008). *C. colocynthis* is mostly used by many diabetics in developing countries (Errajraji *et al.*, 2010; Ziyat *et al.*, 1997). Theirs toxicoses in grazing animals have been suspected by livestock owners especially at time of drought (Adam *et al.*, 2001). The fruits and leaves of this plant contain cucurbitacins A, B, C, and D and α -elaterin and probably other constituents (Nayab *et al.*, 2006; Bakhiet, 1995). The clinical picture of male rats treated with the extract of the fruit of *C. colocynthis*, was characterized by

relatively rapid appearance of symptoms, probably due to the rapid absorption of the active principles present in the fruit extract of the plant. Severe diarrhea was the most serious symptom; after developing it, all the experimental animals died. The animals that survived had some symptoms, including mild diarrhea, but were able to recover. The component(s) of the fruit plant extract responsible for the toxic manifestations after the oral dose are not known. The toxicity and lethality of the fruit-extract may be due to any one or more of the phytochemicals present in the crude methanol extract, some of which have been isolated and identified (Abdel-Hassan *et al.*, 2000; Adam *et al.*, 2001; Chen *et al.*, 2005; Delazar *et al.*, 2006; Yoshikawa *et al.*, 2007). This may be

attributed to the effect of saponin and other constituents of *C. colocynthis*, which, was been known to be a strong laxative since antiquity. This is in agreement with the scientific data of Diwan *et al.* (2000); Bakhiet (1995) and Soulier (1891). The LD₅₀ in male rats is 1311.45 mg/ kg. Given the results of the LD₅₀ (500mg/kg <LD₅₀<5000mg/ kg), the fruit extract of *C. colocynthis* is classified as moderately toxic products as classified by Loomis and Hayes (1996) and Pascoe (1983). In this study, lethal effect started manifesting from 1000mg/kg for male rats. The lethal effect of the plant can be attributed to an increase in blood pressure and/or cardiac arrhythmias (Wasfi, 1994).

Therefore, the LD₅₀ of 1311.45 mg/ kg of the extract is an indication that the extract is not completely safe. However, LD₅₀ has not been regarded as a biological constant because many variables such as animals' species and strain, age, gender, diet, bedding, ambient temperature, caging conditions and time of the day can all affect the LD₅₀ value obtained; hence there are considerable uncertainties in extrapolating LD₅₀ value obtained for specie to other species. Consequently, recognizing LD₅₀ test as providing, at best, only a ball park estimate of human lethality has been advocated (Zbinden and Flury-Roversi, 1981).

In the acute toxicity in male rats given C.C-fruit extract orally at dose 131 mg/kg, there were no changes in animal behavior, but the body weight gains were significantly different in the treated rats as compared to the control. Since, the changes in body weight have been used as an indicator of adverse effects of drugs and chemicals (El Hilaly *et al.*, 2004). The present results suggest that at the oral dose, the C.C-fruit extract is not completely safe. The present study was designed to evaluate the effects of methanol extract of *C. colocynthis* fruit on the liver and kidney of male rats. Liver and kidney are two important organs that perform vital function for the healthy survival of the body. The liver is known to be a key organ in the metabolism and detoxification of xenobiotic, is vulnerable to damage induced by a huge variety of chemicals as reported by Udem *et al.*, 2009.

An obvious sign of hepatic injury is leakage of cellular enzyme into plasma. When the liver cell membrane is damaged, a variety of enzymes normally located in the cytosol are released into blood stream. The estimation of the GPT (glutamic-pyruvic transaminase) and GOT (glutamic- oxaloacetic transaminase) in the serum is useful quantitative marker for the extent and type of hepatocellular damage (Udem *et al.*, 2009; Kumar *et al.*, 2004). An increase in the level of ALP (Alkaline phosphatase) is an indication of biliary obstruction (Udem *et al.*, 2009; Kaneko *et al.*, 1997). The male rats treated with 131 mg/kg of the methanol fruit extract of *C. colocynthis* showed changes in the level of these enzymes after the 1st, 5th, 10th and 14 days of the treatment. The level of ALP showed significant increase in groups C and D. However, rats in Group A and B showed a significant increase in GOT and GPT activity until the 5th day. The maximum acute liver toxicity is expressed at day 5 (Szymanowicz and Danel, 2005). The significant increase in serum GPT activity that was observed in the groups A and B could be an evidence of hepatotoxicity caused by the extract. This result is in agreement with the work

reported by Khatibi (2012), Dehghani and Pananjehshahin (2006) and Diwan *et al.* (2000) in mice.

Furthermore, the elevated serum protein concentration in rats treated with the CCT might be interpreted as a result of deshydration arising from fluid loss during diarrhea. The results obtained showed no change of glycaemia in treated rats, this result is in line with the work reported by Benmehdi *et al.* (2011), who tested the effect of saponosides crude extract isolated from *Citrullus colocynthis* seeds on blood glucose level in rats.

The kidney helps in maintaining homeostasis of the body by reabsorbing important materials and excreting waste products. There was significant difference in the serum levels of urea, creatinine and potassium of the treated animals. Urea is the main end product of protein catabolism and is excreted through urine. Renal diseases which diminish the glomerular filtration lead to urea retention. Creatinine is a waste product formed in muscle by creatine metabolism. Its retention in the blood is evidence of kidney impairment (Wurochekke *et al.*, 2008).

Hematological analysis of plant extract in animals is one of the important methods of assessing the toxicity of plant extract in animals (Ashafa *et al.*, 2009). Haematological studies showed no significant changes in red blood cells and white blood cells after the 1st, 5th, 10th and 14th days of the treatment. But, the RBC, HCT and HGB were highly increased after the 5th day. In those animals, the increased RBC, HGB and HTC was probably due to haemoconcentration arising from fluid loss resulting from profuse diarrhea that developed in the treated animals. This is consistent with the work of Adam *et al.* (2001) on sheep.

CONCLUSION

It can be concluded that fruit extract of *C. colocynthis* is hepatotoxic and has a toxic effect on the kidney. Effort must be exerted to identify plants utilized in folk medicine having narrow therapeutic indices as their use is dangerous and should be carefully researched, especially plants used by diabetic patients.

ACKNOWLEDGEMENTS

The authors thank CNEPRU, for financial support of the project. We also thank Mr R. BENADDI and the staff of Central Analysis Laboratoty, CHU of Sétif, Algeria

REFERENCES

- Abdel-Hassan I.A., Abdel-Barry J.A., Mohammeda S.T. The hypoglycaemic and antihyperglycaemic effect of *Citrullus colocynthis* fruit aqueous extract in normal and alloxan diabetic rabbits. *Journal of Ethnopharmacology*. 2000; 71: 325-30.
- Adam S.E.I., Al-Yahya M.A., Al-Farhan A.H. Combined toxicity of *Cassia senna* and *Citrulluscolocynthis* in rats. *Veterinary and Human Toxicology*. 2001; 43: 70-2.
- Al-Faraj, S. Haemorrhagic colitis induced by *Citrullus colocynthis*. *Ann. Trop.Med. Parasitol*. 1995; 89 (6): 695-696.
- Ashafa A. O. T., Yakubu M. T., Grierson D. S., Afolayan A. J. Toxicological evaluation of the aqueous extract of *Felicia muricata* Thum. Leaves in Wistar rats. *Afr. J. Biotechnol*. 2009; 6: 949-954.
- Atole S.K., Jangde C.R., Philip P., Rekhe D.S., Aghav D.V., Waghode H.J., Chougule A.M. Safety Evaluation Studies of *Citrullus Colocynthis* for diabetes in Rats. *Veterinary World*. 2009; 2: 423-425.

- Bakhiet A.O., Adam S.E.I. An estimation of *Citrullus colocynthis* toxicity for chicks. *Veterinary and Human Toxicology*. 1995; 37: 356-8.
- Benmehdi H., Azzi R., Djaziri R., Lahfa F., Benariba N., Tabti B. Effect of saponosides crude extract isolated from *Citrullus Colocynthis* (L.) seeds on blood glucose level in normal and streptozotocin induced diabetic rats. *Journal of Medicinal Plants Research*. 2011; Vol. 5(31): pp. 6864-6868.
- Blaskovich, M. A., Sun, J., Cantor, A., Turkson, J., Jove, R., Sebt, SM. Discovery of JSI-124 (cucurbitacin I), a selective kinase/signal transducer and activator of transcription 3 signaling pathway inhibitor with potent antitumor activity against human and murine cancer cells in mice. *Cancer Res*. 2003; 63: 1270-9.
- Chen J.C., Chiu M.H., Nie R.L., Cordell G.A., Qiu S. Cucurbitacins and cucurbitane glycosides: structures and biological activities. *Nat. Prod. Rep*. 2005; 22:386-399.
- Dehghani F., Talaie T., Panjehshahin M.R. The toxic effect of alcoholic extract of *Citrullus colocynthis* on mice liver. *Toxicology and Applied Pharmacology*. 2004; 197.
- Dehghani F., Panjehshahin M.R. The toxic effect of alcoholic extract of *Citrullus colocynthis* on rat liver. *J. Pharmacol. Ther*. 2006; 5: 117-119.
- Delazar A., Gibbons S., Kosari A.R., Nazemiyeh H., Modaresi M., Nahar L., Satyajit D.S. Flavone c-glycosides and cucurbitacin glycosides from *Citrullus colocynthis*. *DARU*. 2006; 14:109-114.
- Diwan F.H., Abdel-Hassan I. A., Mohammed S.T. Effect of saponin on mortality and histopathological changes in mice. *Eastern Mediterranean Health Journal*. 2000; 6: 2/3, 345-351.
- El Hilaly J., Israïli Z.H., Lyoussi B. Acute and chronic toxicological studies of *Ajugaivainin* experimental animals. *J. Ethnopharmacol.*, 2004; 91: 43-50.
- Errajaji A., Ouhdouch F., El-Anssari N. Usage des plantes médicinales dans le traitement du diabète de type 2 au Maroc: Use of medicinal plants for type 2 diabetes treatment, in Morocco. *Médecine des Maladies Métaboliques*. 2010 ; 4(3): 301-304.
- Goldfain D., Lavergne A., Galian A., Chauveinc L., Prudhomme F. Peculiar Acute Toxic Colitis after Ingestion of Colocynth a Clinicopathological Study of Three Cases. *Gut*. 1989; 30: 1412-8.
- Husain, A., Virmani, O. P., Popli, S. P., Misra, L. N., Gupta, M. M., Srivastava, G. N. Abraham, Z. and Singh, A. K. Dictionary of Indian Medicinal Plants. CIMAP, Lucknow, India. 1992; 546p.
- Kaneko J.J., Harvey J.W., Bruss M.L. Clinical biochemistry of domestic animals. 5th ed. Academic, USA (1997): 285-302.
- Khatibi R. Relationship between Alcoholics Extract of *Citrullus Colocynthis* and Rat Liver (Case Study: Iran-south East of Iran). *Journal of Agricultural Science*. 2012; 4(1): 219-222.
- Khalil M., Mohamed G., Dallak M., Al-Hashem F., Sakr H., Eid R. A., Adly M. A., Al-Khateeb ., Banihani S., Hassan Z., Bashir N.: The Effect of *Citrullus colocynthis* Pulp Extract on the Liver of Diabetic Rats a Light and Scanning Electron Microscopic Study. *American Journal of Biochemistry and Biotechnology*. 2010; 6 (3): 155-163.
- Kumar S., Kumar D., Manjusha, Saroha K., Singh N., Vashishta B. Antioxidant and free radical scavenging potential of *Citrullus colocynthis* (L.) Schrad. methanolic fruit extract. *Acta Pharmaceutica*. 2008; 58:215-221.
- Kumar G., Sharmila Banu G., Vanitha Pappa P., Sundararajan M., Rajasekara Pandian M. Hepatoprotective activity of *Trianthema portula castrum* L. against paracetamol and thioacetamide intoxication in albino. *J. Ethnopharmacol*. 2004; 92: 37-40.
- Litchfield J. T. and Wilcoxon F. A simplified method of evaluating dose effect experiments. *J. Pharmacol*. 1949; 96: 99-113.
- Loomis T.A., and Hayes A.W. 1996. Loomis's Essentials of Toxicology, 4th Edition, Academic Press, California.
- Nayab D., Ali D., Arshad N., Malik A., Choudhary M.I., Ahmed Z. 2006. Cucurbitacin glycosides from *Citrullus colocynthis*, Pakistane.
- Nmila R., Gross R., Rchid H., Roye M., Manteghetti M., Petit P., Tijane M., Ribes G., Sauvaire Y. Insulinotropic effect of *Citrullus colocynthis* fruit extracts. *Planta Med*. 2000; 66:418-423.
- Pascoe D. 1983. Toxicology. Edward Arnold limited, London.
- Seeger C., Sturm S., Mair M-E., Ellmerer E. P., Stuppner H. 1 H and 13 C NMR signal assignment of cucurbitacin derivatives from *Citrullus colocynthis* (L.) Schrader and *Ecballium elaterium* L. (Cucurbitaceae). *Magn. Reson. Chem*. 2005; 43: 489-491.
- Soulier H. 1891. Traité de thérapeutique et de pharmacologie, Tome II. [Handbook of therapeutics and pharmacology.] Paris.
- Szymanowicz A., Danel V. Toxicological biomarkers in acute intoxications. *Immuno-Anal. Biol. Spécial*. 2005; 20: 144-160.
- Tannin-Spitz T., Bergman M., Grossman S. Cucurbitacin glucosides: Antioxidant and free-radical scavenging activities. *Biochem. Biophys. Res. Comm*. 2007; 364:181-186.
- Udem, S.C., Obidoa, O. and Asuzu, I.U. Acute and chronic toxicity studies of *Erythrina Senegalensis* DC stem bark extract in mice. *Comparative Clinical Pathology*. 2009; 19: 275-282.
- Wasfi I. A. Some Pharmacological Studies on *Citrullus colocynthis*. *Journal of Herbs, Spices & Medicinal Plants*. 1994; 2: 65-79.
- Wurochekke A. U., Anthony A. E., Obidah W. Biochemical effects on the liver and kidney of rats administered aqueous stem bark extract of *Xemenia Americana*. *African Journal of Biotechnology* Vol. 2008; 7 (16): 2777-2780.
- Yaniv, Z.; Shabelsky, E.; Schafferman, D. 1999. Colocynth: Potential arid land oilseed from an ancient cucurbit. *In Perspectives on New Crops and New Uses*, 1st Edition.; Janick, J., Eds.; ASHS Press: Alexandria, VA, USA. 257-261.
- Yoshikawa M., Morikawa T., Kobayashi H., Nakamura A., Matsuhira K., Nakamura S., Matsuda H. Bioactive saponins and glycosides. XXVII. Structures of new cucurbitane-type triterpene glycosides and antiallergic constituents from *Citrullus colocynthis*. *Chem. Pharm. Bull*. 2007; 55:428-434.
- Zamani, M., A.O. Rahimi, R. Mahdavi, M. Nikbakhsh and M.V. Jabbari, Assessment of anti-hyperlipidemic effect of *Citrullus colocynthis*. *Braz. J. Pharma*. 2007; 17: 492-496.
- Zbinden G. Flury-Roversi M. Significance of the LD₅₀ test for the toxicological evaluation of chemical substances. *Arch. Toxicol*. 1981; 4792: 77.
- Ziyyat A., Legssyer A., Mekhfi H, Dassouli A., Serhrouchni M., Benjelloun W. Phytotherapy of hypertension and diabetes in oriental Morocco. *Journal of Ethnopharmacology*. 1997: 58: 45-54.

How to cite this article:

Soufane, S., A. Bedda, N. Mahdeb., A. Bouzidi., Acute Toxicity study on *Citrullus colocynthis* fruit methanol extract in Albino rats. *J App Pharm Sci*. 2013; 3 (06): 088-093.