

ISSN:2231-3354
 Received: 12-06-2011
 Revised : 14-06-2011
 Accepted: 19-06-2011

Effect of ginger (*Zingiber officinale* R.) on metiram-inhibited spermatogenesis and induced apoptosis in albino mice

Saber A. Sakr and Gamal M. Badawy

ABSTRACT

The effect of ginger (*Zingiber officinale* R.) on metiram fungicide induced testicular damage in albino mice was studied. Treating mice with metiram at a dose level of 1/10 LD₅₀ (284 mg/kg body weight) daily for 6 weeks affected the testicular tissue. The diameters of the seminiferous tubules and heights of their germinal epithelium were significantly reduced. In addition, spermatogenesis was inhibited as indicated by the decrease of the number of different spermatogenic cells. Histological observations revealed degeneration of spermatogenic cells, congestion of blood vessels and destruction of Leydig cells. Evidences of apoptosis were observed in large number of basal germ cells. Moreover, significant higher numbers of Bax-positive germ cells and Leydig cells was recorded in metiram-treated mice. These results indicated that metiram affected spermatogenesis. Treating animals with metiram followed by ginger revealed an improvement in the histological changes observed in animals treated with metiram. Moreover, ginger treatment leads to a decrease in the percent of apoptotic cells and in the number of bax-positive cells. According to the present results, it is concluded that combined treatment with metiram and ginger can improve the histological alterations and reduce apoptosis in testis of mice. The ameliorative effect of *Z. officinale* against testicular damage induced by metiram may be due to its antioxidant properties.

Key words: Metiram; Ginger; Mice; Testis; Apoptosis, Spermatogenesis.

INTRODUCTION

Apoptosis or programmed cell death is a tightly controlled physiological process by which damaged cell are eliminated from the cellular population (Wyllie, 1992). Recent studies proved that oxidative stress is an apoptotic inducer (Ratan et al., 1994; Chandra et al., 2000). Many agents that induce apoptosis are either oxidants or stimulators of cellular oxidative metabolism. Conversely, many inhibitors of apoptosis have antioxidant activities or enhance cellular antioxidant defenses (Qin et al., 2001). Metiram (polyram) is a non-systemically acting fungicide of dithiocarbamate group. Metiram was registered for use on food and ornamental crops to prevent crop damage in the field and to protect harvested crops from deterioration in storage or transport (Charls et al., 2000). On the other hand, metiram showed toxicity to mammalian animals. Using alkaline unwinding assay DNA, Kornuta et al., (1996) reported that metiram is one of the pesticides which showed genotoxic effect. Dermal administration of metiram resulted in minimal to moderate exfoliation and ulcerative dermatitis in the skin of rabbits treated at the high-dose level (Ullmann et al., 1987). Sortwell et al., (1977) reported follicular hyperplasia in thyroid of female rhesus monkeys treated with metiram. The effect of the fungicides (maneb, metiram, and ziram) on human natural killer (NK) cells cytotoxic function was studied by Whalen et al., (2003).

Saber A. Sakr, Gamal M. Badawy
 Department of Zoology,
 Faculty of Science, Menoufia
 University, Shebin El-kom, Egypt.

***For Correspondence:**

Saber A. Sakr
 Department of Zoology,
 Faculty of Science, Menoufia
 University, Shebin El-kom, Egypt.
 Email- sabsak@yahoo.com

Their results provide evidence of relative toxic potential for these compounds and the immunomodulatory effects on both T and NK lymphocyte function. Sakr et al., (2009) reported that metiram induced histopathological as well as biochemical alterations in the liver of albino mice.

Accumulating evidence suggests that many dietary factors may be used alone or in combination with traditional chemotherapeutic agents to prevent or treat diseases. Ginger (*Zingiber officinale* Roscoe) is example of medicinal plants which is gaining popularity amongst modern physicians and its underground rhizomes are the medicinally useful part (Mascolo et al., 1989). Many studies were carried out on ginger and its pungent constituents, fresh and dried rhizome. One of the most popular uses of ginger is to relief the symptoms of nausea and vomiting associated with motion sickness, surgery and pregnancy (Gilani and Rahman, 2005). Ginger extract has recently been shown to have a variety of biological activities, including anticancer, anti-oxidation, anti-inflammation and antimicrobial properties (Fisher-Rasmussen et al., 1991, Sharma et al., 1994, Kamtchouing et al., 2002). Ginger was found to have hypocholesterolaemic effects and cause decrease in body weight, glucose in blood, serum total cholesterol and serum alkaline phosphatase in adult male rats (Bhandari et al., 2005). All Ginger's major active ingredients, such as zingerone, gingerdiol, zingibrene, gingerols and shogaols, are known to possess anti-oxidant activities (Zancan et al., 2000). Ginger was also found to possess a protective against DNA damage induced by H₂O₂ and enhanced sperm healthy parameters in rats (Khaki et al., (2009). The present study was designed to investigate the effects of ginger extract on metiram induced-testicular damage in albino mice.

MATERIALS AND METHODS

Animals

Eighty sexually mature male albino mice weighing 20±5 g were purchased from the breeding center of experimental animals at Helwan University, Helwan, Egypt. The animals were kept in the laboratory under constant temperature (22±1°C) for at least one week before and along the period of the experimental work. They were maintained on a standard rodent diet composed of 20% casein, 15% corn oil, 55% corn starch, 5% salt mixture and 5% vitaminized starch (Egyptian Company of Oils and Soap Kafr-Elzayat Egypt). Water was available *ad libitum*.

Preparation of ginger aqueous extract

Ginger (*Z. officinale* Roscoe) rhizome was purchased from the local market at Shebin El-kom, Egypt. One kilogram fresh ginger rhizome was cleaned, washed under running tap water, cut into small pieces, air dried and powdered. 125 g of this powder were macerated in 1000 ml of distilled water for 12 h at room temperature and were then filtered. The concentration of the extract is 24 mg/ml. Each experimental animal in the present study was orally given 1 ml of the final aqueous extract (Kamtchoving et al., 2002).

Experimental design

Animals were divided into 4 groups:

- Group 1: Animals of this group (20 mice) were orally given 1/10 LD₅₀ (284 mg/kg b.w.) of metiram daily for 6 weeks dissolved in distilled water. It consists of 80% active ingredients [zinc ammoniate ethylenebis (dithiocarbamate)-poly (ethylenethiuram disulfide) and 20% inert ingredients.
- Group 2: Animals in this group (20 mice) were given the same dose of metiram given to animals of group 1 followed by 1 ml of final aqueous extract of ginger (24 mg/ml) three times weekly for 6 weeks.
- Group 3: Animals of this group (20 mice) were orally given ginger at the same dose level of group 2.
- Group 4: This group (20 mice) is a control one (untreated).

Histological preparations

Animals were sacrificed by cervical decapitation after 4 and 6 weeks of treatment and were dissected, testes were removed from treated and control mice and fixed in 10% formalin. After fixation, specimens were dehydrated in an ascending series of alcohol, cleared in two changes of xylene and embedded in molten paraffin. Sections of 5 microns thickness were cut using rotary microtome and mounted on clean slides. For histopathological examination, sections were stained with Ehrlich's haematoxylin and counterstained with eosin.

Analysis of Bax Expression

Bax protein products were detected by specific monoclonal antibodies. From each liver block, 4-µm-thick sections were cut on Neoprene-coated slides. The immunostaining was performed using the avidin—biotin complex (ABC) method and an automatic autostainer (CODE-ON Immuno/DNA slide stainer: Biotek solution, Santa Barbara, CA). Slides were deparaffinized and blocked for endogenous peroxidase with 1.75% hydrogen peroxide in methanol for 20 min, antigen retrieval for 15 min using Biogenex Antigen Retrieval Citra solution in 90°C water bath for 30 min. The slides were allowed to cool for 20 min before continuing. Slides were then blocked by normal horse serum for 5 min at 37°C. The monoclonal antibody was applied overnight in humid medium at room temperature followed by the biotinylated secondary antibody for 15 min at 37°C and the ABC complex for 15 min at 37°C (Vectastain Elite ABC Kit; Vector Laboratories, Burlingame, CA). Diaminobenzidine (DAB) was applied for 20 min at room temperature as chromogen, slides were counterstained with hematoxylin, dehydrated, and covered by coverslips. In negative control slides, the same system was applied with replacement of the monoclonal antibody by diluted normal bovine serum. Bax immunostaining was performed using polyclonal rabbit-anti-human (A3533 Ig fraction; Dako, Glostrup, Denmark) at a dilution of 1:50.

DNA Fragmentation Assay

As a measure of apoptotic DNA fragmentation, the presence of DNA ladder was determined according to Wlodek et

al.(1991). Extraction of DNA was done according to the method of (Aljanabi and Martines, 1997). 10 mg of testicular tissue in eppendorf tubes were lysed with 600 microlitre buffer (50 mM NaCl, 1 mM Na₂EDTA, 0.5% SDS, PH 8.3) and gently shaken. The mixture was incubated overnight at 37 C^o then, 20 microlitre of saturated NaCl was added to the sample, shaken and centrifuged at 12,000 rpm for 10 min. the supernatant was transferred to new eppendorf tubes and then DNA precipitated by 600 microlitre cold isopropranol. The mix was inverted several times till fine fibres appear, and then centrifuged for 5 min. at 12,000 rpm. The supernatant is removed and the pellets were washed with 500 microlitre 70% ethyl alcohol centrifuged at 12,000 rpm for 5 min. After centrifugation the alcohol was decanted or tipped out and the tubes plotted on Whatman paper to be dry. The pellets were resuspended in 50 microlitre or appropriate volume of TE buffer (10 mM Tris, 1 mM EDTA, PH 8). The resuspended DNA was incubated for 30 - 60 min with loading mix (Rnase + loading buffer) and then loaded into the gel wells.

Agarose gel electrophoresis

A gel was prepared with 2% agarose containing 0.1% ethidium bromide (200 ug/ml). The DNA samples were mixed with loading buffer (0.25% bromophenol blue, 0.25% xylene cyanole FF and 30% glycerol) and loaded into the wells (2 ug of DNA/lane) with a standard molecular- sized ladder marker (Pharmacia Biotech., USA). The gel was electrophoresed at a current of 50 mA for 2.5 h using the submarine gel electrophoresis machine. The DNA was visualized and photographed with illumination under UV light using a photodocumentation hood (Fisher Scientific, Pittsburgh, PA, USA) equipped with a Polaroid 667 film with an orange filter (Kodak, Rochester, NY, USA).

Statistical Analysis

The results were expressed as mean \pm SD of different groups. The differences between the mean values were evaluated by ANOVA followed by Student's "t" test using Minitab 12 computer program (Minitab Inc., State Collage, PA).

RESULTS

Histological observations

Histological examination of testis of control mice revealed a picture of full spermatogenic activity. The germ cells and Sertoli cells within the seminiferous tubules were normal, as were the interstitial (Leydig) cells (Fig. 1a). No histological alterations were observed in animals treated with ginger. Testes of animals administered with metiram for four weeks exhibited a distinct histological difference when compared with control ones. In testes of these animals, large numbers of seminiferous tubules appeared irregular and sometimes were with thick basement membranes. Hemorrhage was seen in the degenerated intertubular connective tissue which appeared with different vacuoles (Fig.1b). The seminiferous tubules were found to contain few spermatogonia and degenerated spermatocytes which exfoliated in the lumen of the tubules (Fig.1c). Apoptotic cells whose nuclei were condensed, dark and fragmented were seen in the basal germ layer (Fig.1d).

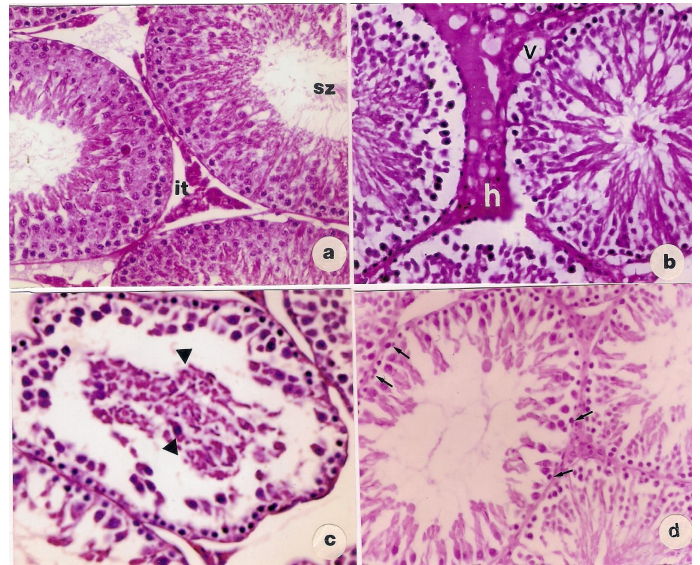


Fig.1. Sections of testes. (a) A control mouse showing normal spermatogenic cells, spermatozoa (SZ) and interstitial tissue (IT). (b) Metiram treated mouse for 4 weeks showing intertubular hemorrhage (h). (c) Exfoliated degenerated cells in the lumen of the tubule (arrow heads), (d) Basal germ cells showing apoptosis (arrows). (H&E, X 400).

These histopathological alterations were more obvious in animals treated with metiram for 6 weeks. In these specimens, the seminiferous tubules were more affected; there was decrease in the number of germ cells leading to enlargement of the lumens. In addition, the sperm bundles were less abundant and apoptosis was observed (Fig.2a). Examination of testes of animals treated for four weeks with metiram and ginger revealed less prominent histopathological changes when compared with the same period of metiram group. Advanced degree of improvement was seen in testes of animals treated for 6 weeks with metiram and ginger. Most of the seminiferous tubules were compact with each other with few or no apoptosis. An increase of spermatogenic cells and an increase in the number of mitotic figures were seen (Fig.2b).

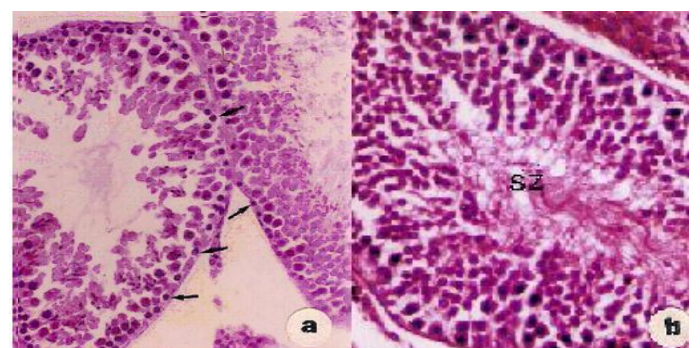


Fig.2 (a).Seminiferous tubules of metiram treated mouse for 6 weeks showing arrest of spermatogenesis and basal germ cells apoptosis (arrows). (b) Seminiferous tubules of metiram and ginger treated mouse showing an increase in the cellularity of spermatogenic layers and spermatozoa (SZ) filled the lumen (H&E, X 400).

Morphometric Results

Figure (3a&b) showed the morphometric changes in the diameter of seminiferous tubules and their epithelial heights. Treating mice with metiram for 4 or 6 weeks showed significant decrease ($P < 0.05$) in tubules diameters and their epithelial heights.

On the other hand, animals treated with metiram and ginger for the same periods showed highly significant increase in the diameter of seminiferous tubules and their epithelial heights in comparison with metiram group. No significant changes were recorded in tubules diameter or epithelial height of ginger-treated mice compared with control animals.

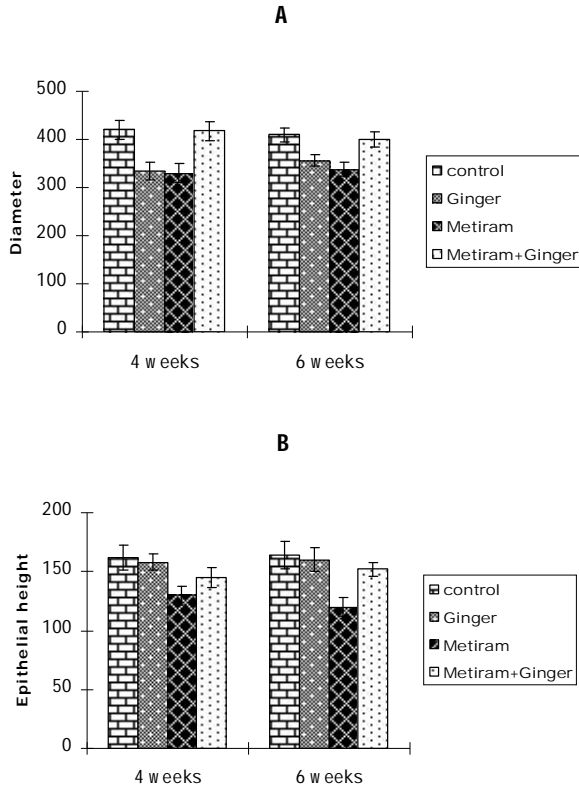


Fig. 3. Effect of different treatments on; (A) diameter and (B) the epithelial height of seminiferous tubules (mean ± SD).

Bax Expression

Figure 4 (a & b) showed bax positive staining germ cells and Leydige cells in mice given metiram. Figure 5 showed that the percentage of bax positive germ cells was significantly increased in animals treated with metiram. On the other hand, animals treated with metiram and ginger showed a significant reduction in the percentage of these cells after 6 weeks.

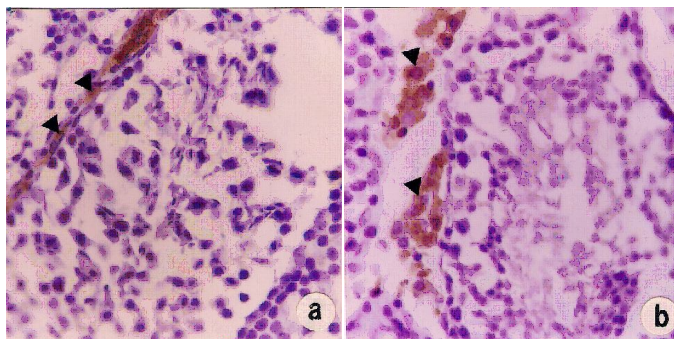


Fig.4. Seminiferous tubules of metiram treated mice showing (a).basal germ cells and (b). Leydige cells (arrow heads),(Bax immunostaining, X 400).

Biochemical features of apoptosis

DNA isolated from testicular tissue of mice treated with metiram for 4 and 6 weeks showed degradation into oligonucleotide fragments forming a clear laddering pattern of apoptosis when separated by agarose gel electrophoresis (Fig.6). On the other hand, treating animals with metiram and ginger revealed decrease of apoptosis as indicated in lane 4.

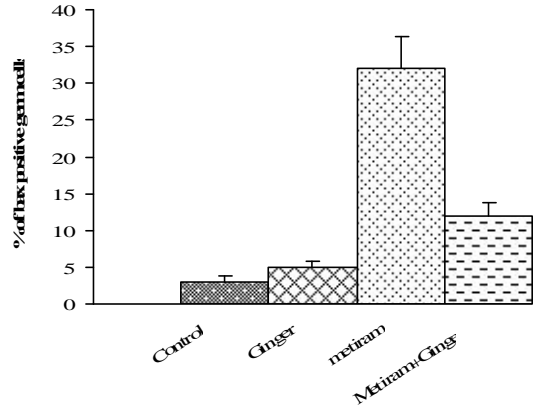


Fig.5. Histogram showing the percentage of bax positive germ cells in different animal groups.

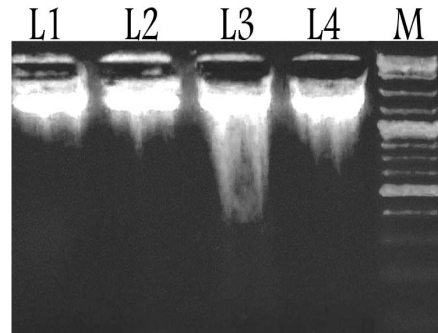


Fig.6. Gel electrophoresis of testicular DNA. Lane 1: control, lane 2: ginger, Lane 3: metiram group and lane 4: metiram and ginger group. M: standard lane.

DISCUSSION

The present results showed that metiram affected the testicular tissue of mice. The histological as well as the morphological results revealed that spermatogenesis was inhibited. Similar results were obtained in experimental animals exposed to some fungicides. Khan and Sinha (1994) demonstrated that there was a decrease in sperm count and a higher frequency of sperm with aberrant head morphology in mice exposed to mancozeb. Kackar et al., (1999) also reported that mancozeb caused histopathological changes in gonads of male rats after chronic exposure. These changes include a significant increase in testes and decrease in epididymis weights, degeneration in seminiferous and epithelial tubules with loss of sperm. Sakr and Okdah (2004) studied the effect of benomyle fungicide on the testis of albino mice. Their results showed a degeneration of the spermatogenic cells, absence of sperm bundles and a significant reduction in the

diameter of the seminiferous tubules and the height of the germinal epithelium. Vinclozolin fungicide was found to have anti – androgenic effects on spermatogenesis in male rat testis (Kubota et al., 2003). Blystone et al., (2007) reported that the fungicide prochloraz induced malformations in androgen-dependent tissues in male rats when administered during sex differentiation.

In this study, exposure of mice to metiram leads to testicular apoptosis. In addition, a significant numbers of Bax-positive cells were found in basal germ cells and Leydige cells of metiram-treated mice, indicating that these cells are susceptible to apoptosis. Similarly, Yu et al., (2009) reported that carbendazim has adverse effects on spermatogenesis, resulting in reduced fertility in male rats. They added that the apoptosis rate and Bax expression were significantly raised, while the expression of Bcl-2 significantly decreased. Cowin et al., (2010) demonstrated that *in utero* vinclozolin increased germ cell apoptosis, reduced concentration of elongated spermatids and postpubertal prostatitis. The mechanisms through which metiram may produce apoptosis in testicular tissue have not been previously investigated. The link between oxidative stress and apoptosis was recorded (Buttke and Sandstorm, 1994). Besides oxidative damage directly inflicted on DNA by free radical, there are other indirect mechanisms by which radicals can cause destruction of the genome. As already reported, lipid peroxides enter the nucleus where they react with Fe⁺² to generate the aloyl radical which attacks DNA (Frag and Tappel, 1988). Also, intracellular calcium levels increase as a result of oxidation damage to membranes, calcium then enters the nucleus where it can activate nucleases which lead to DNA fragmentation (McConkey et al. 1989). Marked reduction in antioxidant enzymes activities and tissue glutathione contents resulted in oxidative damage of tissues (Sharma et al., 1991). The depletion of glutathione is sufficient for the onset of apoptosis in cellular systems (Nakatani et al., 2000). One or more of this mechanism are responsible for induction of apoptosis by metiram.

Treating animals with ginger extract decreased testicular damage induced by metiram as shown by increase of spermatogenic cells. In agreement with this result, Qureshi et al., (1989) reported that ginger (*Zingiber officinale*) significantly increased the sperm mortality and sperm contents in the epididymis and vas deference without producing any spermatotoxic effect. Kamtchoving et al., (2002) investigated the androgenic activity of aqueous extract of *Z. officinal* in male rats. They reported that *Z. officinal* significantly increased weight of testes, the serum testosterone level and epididymal α -glucosidase activity. Also Amin and Hamza (2006) studied the protective effect of ethanol extract of *Z. officinal* against cisplatin-induced reproductive toxicity in rats They demonstrated that *Z. officinal* extract reduced the extent of cisplatin- induce sperm abnormality, enhanced sperm motility and testicular damage by increase the activities of testicular antioxidants. Khaki et al., (2009) reported that administration of ginger significantly increased sperm percentage, viability, motility and serum total testosterone in rats. Ginger rhizome was found to overcome reproductive toxicity of gentamicin and induced spermatogenesis through the elevation of

testosterone levels (Zahedi et al., 2010). Hafez (2010) reported that intake of ginger roots as a drink may be beneficial for diabetic patients who suffer from sexual impotency as their extracts induce antidiabetic activity and enhance male fertility in diabetic rats.

Ginger leads to suppression of apoptosis induced by metiram. Amin et al., (2008) reported that ginger attenuated the testicular damage and decreased apoptotic damage both in testes and sperms. It also retained the control value of p53 protein expression in the testicular tissue. Khaki and khaki (2010) found that ginger significantly decreased the adverse harmful effects of lead acetate exposure on the liver as well as lead acetate-induced apoptosis. Ginger has been proven to suppress apoptosis of 1,2 dimethylhydrazine-induced colon cancer. (Manju and Nalini 2005).

Ginger extracts have been extensively studied for a broad range of antioxidant activities. Morakinyo et al., (2008) indicated that extract of *Zingiber Officinale* possesses pro-fertility properties in male rats which might be a product of both its potent antioxidant properties and androgenic activities. Treating diabetic rats with ginger for twenty consecutive days significantly increased sperm motility and viability and decreased lipid peroxidation (Nassiri et al., 2009). Morakinyo et al., (2010) reported that co-administration of aqueous ginger extract with arsenite was found to protect against adverse change in the reproductive organ weight, attenuate the decrease in sperm functions, enhance plasma reproductive hormones level along with increased antioxidants activities and reduced peroxidation. The antioxidant activity of ginger (*Zingiber officinale*) was attributed to its major ingredients namely Zingerone, gingerdiol, Zingiberene, gingerols and shogols (Zancan et al., 2002). Siddaraju and Dharmesh (2007) elucidated that ginger-free phenolic and ginger hydrolysed phenolic fractions of ginger exhibited free radical scavenging, inhibited lipid peroxidation, DNA protection and reduced power abilities indicating strong antioxidant properties.

In conclusion, results of the present study revealed that, ginger extract ameliorated metiram-induced testicular damage and apoptosis in albino mice. This effect may be mediated by the antioxidant and direct free radicals scavenging activity of ginger extracts.

REFERENCES

- Aljanabi, S.M. and Martines, I. Univesal and rapid salt extraction of high quality genomic DNA for PCR based technique. *Nucleic Acids Res.* 1997, 25:4692-4693.
- Amin A, Hamza A.: Effects of Rosell and ginger on cisplatin-induced reproductive toxicity in rats. *Asian J. Androl.* 2006, 8: 607–12.
- Amin A, Hamza A, Kambal A, Daoud S. Herbal extracts counteract cisplatin-mediated cell death in rat testis. *Asian J Androl.* 2008, 10: 291–7.
- Bhandari U, Kanojia, R, Pillai, KK Effect of ethanolic extract of *Zingiber officinale* on dyslipidaemia in diabetic rats. *J. Ethnopharm.,* 2005, 97:227-230
- Bhandari, U., Sharma, J.N. and Zafar, R. The protective action of ethanolic ginger (*zingiber officinale*) extract in cholesterol fed rabbits. *J. Ethnopharmacol.* 1998, 61(2):167-171.
- Blystone C, Lambright C, Howdeshell K, Furr J, Sternberg R, Butterworth B, Durhan E, Makynen E, Ankley G, Wilson V, Leblanc G, Gray L. Sensitivity of fetal rat testicular steroidogenesis to maternal prochloraz exposure and the underlying mechanism of inhibition. *Toxicol Sci.* 2007, 97:512–9.

- Buttke T, Sandstorm P. Oxidative stress as a mediator of apoptosis. *Immunol. Today*. 1994, 15: 7–10.
- Chandra J, Samali A, Orrenius S. Triggering and modulation of apoptosis by oxidative stress. *Free Radic. Biol. Med.* 2000, 29: 323–32.
- Charles J, Tobia A, Ravenzwaay B. Subchronic and chronic toxicological investigations on metiram: The lack of a carcinogenic response in rodents. *J Toxicol. Sci.* 2000, 54:481–92.
- Cowin P, Gold E, Aleksova J, O'Bryan M, Foster P, Scott H, Risbridger G. Vinclozolin exposure in utero induces postpubertal prostatitis and reduces sperm production via a reversible hormone-regulated mechanism. *Endocrinology*. 2010, 151:783–92.
- Farag C, Tappel A. Damage to DNA concurrently with lipid peroxidation in rat liver slices. *Biochem. J.* 1988, 252, 893–6.
- Fisher-Rasmussen, W. and Kjaer, S, Dahl C, Asping U. Ginger treatment of *Hyperemesis gravidarum*. *Eur. J. Obst. Gynecol. Rep. Bio.* 1991, 38:19–24.
- Gilani A, Rahman A. Trends in ethnopharmacology. *J. Ethnopharmacol.* 2005,100:43–9.
- Hafez D. Effect of extracts of ginger roots and cinnamon bark on fertility of male diabetic rats. *J. American Science.* 2010, 6:940–7.
- Kackar R, Srivastava M, Raizada R. Induction of gonadal toxicity to male rat after chronic exposure to mancozeb. *Ind. Health.* 1999, 35: 104–11.
- Kamtchoving P, Mbongue Fndio G, Dimo T, Jatsa H. Evaluation of androgenic activity of *Zingiber officinale* and *Pentadiplandra brazzeana* in male rats. *Asian J. Androl.* 2002, 4:299–301.
- Khaki A, Khaki A. Antioxidant effect of ginger to prevents lead-induced liver tissue apoptosis in rat. *J. Medicinal Plants Res.* 2010, 4: 1492–5.
- Khaki A, Fathiazad F, Nouri M Khaki A, Chelar C, ozanci, Ghafari-Novin M, Hamadeh M. The Effects of Ginger on Spermatogenesis and Sperm parameters of Rat. *Iranian J. Reprod. Med.* 2009, 7: 7–12.
- Khan P, Sinha S. Impact of higher doses of vitamin C in modulating pesticide genotoxicity Teratog. *Carcinog. Mutagen.* 1994, 14:175–81.
- Kornuta N, Bagley E, Nedopitanskaya N. Genotoxic effects of pesticides. *J Environ Pathol Toxicol Oncol.* 1996,15:75–8.
- Kubota K, Ohsako S, Kurosawa S, Takeda K, Qing W, Sakaue M, Kawakami T, Ishimura R, Tohyama C. Effects of vinclozolin administration on sperm production and testosterone biosynthetic pathway in adult male rat. *J Reprod Dev.* 2003, 49:403–12.
- Manju V, Nalini N. Chemopreventive efficacy of ginger, a naturally occurring anticarcinogen during the initiation, post-initiation stages of 1,2 dimethylhydrazine-induced colon cancer. *Clin. Chim. Acta.* 2005, 358:60–7.
- Mascolo N, Jain R, Tain S, Capasso F. Ethnopharmacologic investigation of ginger (*Zingiber officinale*). *J. Ethano Pharmacol.* 1989, 27: 129–40.
- McConkey D, Hartzell P, Jondal M, Orrenius S. Inhibition of DNA fragmentation in thymocytes and isolated thymocyte nuclei by agents that stimulate protein kinase. *C. J. Biol. Chem.* 1989, 264: 399–402.
- Morakinyo A, Adeniyi O, Arikawe A. Effects of *Zingiber Officinale* on Reproductive Functions in the Male Rat. *Afr. J. Biomed. Res.* 2008, 11: 329 – 34.
- Morakinyo A, Achema P, Adegoke O. Effect of *Zingiber Officinale* (Ginger) on Sodium Arsenite-Induced Reproductive Toxicity in Male Rats. *Afr. J. Biomed. Res.* 2010, 13: 39–45.
- Nakatani T., Tawaramato M., Kennedy D, Kojima A, Yuasa I. Apoptosis induced by chelation of interacellular zinc is associated with depletion of cellular reduced glutathione level in rat hepatocytes. *Chem. Biol. Interact.* 2000, 125: 51–163.
- Nassiri M, Khaki A, Ahmadi-Ashtiani H, Rezazadeh S, Rastgar H, Gharachurlu S. Effects of ginger on spermatogenesis in streptozotocin-induced diabetic Rat. *J.Medicinal Plants.* 2009, 8:118–24.
- Qin F, Rounds N, Mao W, Kawai K, Liang C. Antioxidants vitamins prevent cardiocyte apoptosis produced by norepinephrine infusion in ferrets. *Cardiovasc.Res.* 2001, 51: 736–48.
- Qureshi S, Shah A. Tariq M, Ageel, A. Studies on herbal aphrodisiacs used in Arab system of medicine. *Am. J. Chin. Med.* 1989, 17:57–63.
- Ratan , R., Murphy, T., , Baraban, J. Oxidative stress induces apoptosis in embryonic cortical neurons. *J. Neurochem.* 1994, 62, 376-379.
- Sakr S, Okdah Y. Histological and histochemical alteration induced in the testicular tissue of mice intoxicated with benomyle. *J.Biol. Sci.* 2004, 4: 498–500.
- Sakr S, ElKenawy A, El-Sahara D. Protective effect of licorice on metiram fungicide induced liver injury in mice. *Canadian J. Pure Appl.Sci.* 2009,3:787–93.
- Sharma G., Nath R, Gill K.. Effects of ethanol on cadmium-induced lipid peroxidation and antioxidant enzymes in rat liver. *Biochem. Pharmacol.* 1991: 9–16.
- Sharma J, Srivastava K, Gan E. Suppressive effects of eugenol and ginger oil on arthritic rats. *Pharmacol.* 1994, 49: 314–8.
- Siddaraju M, Dharmesh S. Inhibition of gastric H⁺, k⁺, ATPase and *Helicobacter pylori* growth by phenolic antioxidants of *Zingiber officinale*. *Mol. Nutr. Food. Res.* 2007, 51: 324–32.
- Sortwell R, Heywood R, Allen D. Metiram preliminary oral toxicity study in Rhesus monkeys. Repeated dosage for 4 weeks. Huntingdon Research Centre, Huntingdon, England submitted to WHO by BASF Aktiengesellschaft, FRG (1977).
- Ullmann L.; Sacher R, Porricello T. Report on the subacute 21-day related-dose dermal toxicity study with polyram in rabbits . Research and Consulting Company AG, Switzerland. Submitted to WHO by BASF Aktiengesellschaft, FRG (1987).
- Whalen M, Loganathan B, Yamashita N, Saito T. Immunomodulation of human natural killer cell cytotoxic function by triazine and carbamate pesticides. *Chem Biol Interact.* 2003,145: 311–19.
- Wlodek, D.; Banath, J. and Olive, P.L. Comparison between pulsed-field and constant-field gel electrophoresis for measurement of DNA double-strand breaks in irradiated Chinese hamster ovary cells. *Int. J. Radiat. Biol.* 1991, 60(5): 779-790
- Wyllie, A.H. Apoptosis and the regulation of cell numbers in normal and neoplastic tissues: An overview. *Cancer Metastasis Rev.* 1992, 11, 95-103.
- Yu G, Xie L, Liu Y, Wang X. Carbendazim affects testicular development and spermatogenic function in rats. *Zhonghua Nan Ke Xue.* 2009, 15: 505–10.
- Zahedi A, Khaki A, Ahmadi-Ashtiani H, Rastegar H, Rezazadeh S. *Zingiber officinale* Protective Effects on Gentamicin's Toxicity on Sperm in Rats. *J Medicinal Plants.* 2010, 9: 93–8.
- Zancan K, Marques M, Petenate A, Meireles M. Extraction of ginger (*Zingiber officinale*) oleoresin with CO₂ and co-solvent: a study of the antioxidant action of the extracts. *J. Superit. Flu.* 2002, 24: 57–76.