



ISSN: 2231-3354
Received on: 12-05-2012
Revised on: 19-05-2012
Accepted on: 24-05-2012
DOI: 10.7324/JAPS.2012.2630

Histopathological Responses of the Heart, Liver and Kidney to *Calliandra Portoricensis* Extracts in Wistar Rats Challenged with Venom of *Echis Ocellatus*

Onyeama HP, Ebong PE, Eteng MU, Igile GO, Ibekwe HA and Ofemile PY

Onyeama HP
National Veterinary Research
Institute, Vom, Plateau State,
Nigeria.

Ebong PE, Eteng MU, Igile, GO
Department of Biochemistry,
College of Medical Sciences,
University of Calabar, Calabar,
Cross River State, Nigeria.

Ibekwe HA
Department of Animal Science,
Cross River University of Technology,
Obubra Campus, Nigeria.

Ofemile PY
Department of Pharmacology,
Faculty of Veterinary Medicine,
Ahmadu Bello University,
Zaria, Kaduna State, Nigeria.

For Correspondence
Onyeama HP
National Veterinary Research
Institute, Vom, Plateau State,
Nigeria.
Tel.: +2348033532972.

ABSTRACT

This study was designed to evaluate the efficacy of *Calliandra portoricensis* extracts in ameliorating the histopathological changes in the heart, liver and kidney of wistar rat challenged with venom of *Echis ocellatus*. A total of 30 rats were randomly assigned into 5 treatment groups of 6 rats each. Group 1 (control) received nothing. Group 2 received 200µg venom/rat. Groups 3, 4 and 5 received, in addition to the same amount of venom, 0.5 ml of 100mg/100g body weight of rat as "antidote" concentration 4 hours after the administration of the venom. The dosages of the venom and the extracts were administered intramuscularly and after 4 hours the heart, liver and kidney were harvested for histopathological study of the changes in these organs. The groups treated with the extracts showed reduction in tissue injury compared to the venom alone, though not as good as the control group. This reduction is more marked in treatment group 4, which is polyphenol-rich and which is believed to be the component that is involved in complexation with the venom. This implies a restoration of these organs to a near normal state after the viperian envenomation.

Keywords: Histopathological, Venom, *C.portoricensis*, Heart, Liver, Kidney.

INTRODUCTION

Carpet viper (*Echis ocellatus*) along with other true and pit vipers, is the venomous snake responsible for most deaths in snakebite cases in the north-eastern and central parts of Nigeria. For the last century, polyvalent anti-venom (PVA) is the only available specific treatment. However, PVA does not provide enough protection against venom-induced haemorrhage, necrosis, nephrotoxicity and often develops hypersensitivity reactions (Sutherland, 1977; Corrigan *et al*, 1978). Carpet viper venom induces a quantitatively similar pathophysiological picture, characterized by immediate and prominent local tissue damage (myonecrosis, edema, haemorrhage and hypovolemic shock) and coagulation disorders (defibrination) which might end in acute renal failure (Amoral *et al*, 1985).

If anti-venom administration is initiated rapidly after envenomation neutralization of system effects usually is achieved successfully, but elimination of local tissues damage is a more difficult task. In a number of snakebite cases, lack of neutralization of local effects results in permanent tissue damage and organ dysfunction. It is important to point out that in Nigeria and elsewhere, the production of antiophidic serum is almost destined or exclusive to human accidents, leaving uncovered animals of high economic value. It has therefore, become necessary to look for new methods to neutralize these toxins. Although known conventional method of treatment of snake envenomation using PVA had been in existence, this is not readily achievable in rural settings in Nigeria as a result of erratic power supply for the preservation of the PVA. The PVA in addition to its known anaphylactic reactions in some people is expensive and unaffordable to the rural people who constitute the majority of snakebite victims. Phytotherapy therefore becomes the accessible and affordable choice of treatment of snakebite victims.

In phytotherapy of snakebites specifically of the viperian species, traditional herbalists in south eastern part of Nigeria have found the leaves and roots of *Calliandra portoricensis* valuable in neutralizing viperian venom. A phytochemical screening of *C. portoricensis* leaf and root extracts revealed the presence of flavonoids and polyphenols, more specifically 2-Hydroxy-4-methoxy benzoic acid, a secondary metabolite which probably carries out nucleophilic attack on some of the numerous hydrolytic enzymes in viperian venom. This study was therefore carried out to ascertain the effects of the various *C. portoricensis* extracts on the tissue alterations caused on the heart, liver and kidney by viperian venom using wistar rat model.

MATERIALS AND METHOD

Source of Venom

Lyophilized snake venom of carpet viper was purchased from South African venom suppliers cc; bewild@worldonline.co.za. This venom was preserved as a yellowish crystal inside a tube surrounded by blueish larger silica gel to maintain a dry environment. This was then kept in a dessicator at 8°C till it was used.

Source of Plant

Calliandra portoricensis was sourced from the extensive secondary forest of Oji-River in Enugu State where it is used traditionally in the treatment of snakebite of the viperian species. Taxonomically, the plant was identified and confirmed to be *C. portoricensis* by Professor Jonathan C. Okafor, Professor of Botanical Taxonomy, Ebonyi State University, Abakaliki, Nigeria. Voucher specimen "CP-O No.1" has been preserved for reference in the Botany Herbarium of Ebonyi State University, Abakaliki.

Plant Extract

Three hundred and fifty grammes (350g) each of fresh and dry leaves and roots were crushed separately and extracts prepared from them by refluxing them in 80% ethanol for 72 hours in a

Soxhlet extractor. The extracts were then concentrated in rotary evaporator and dissolved in 0.9% saline for use.

Phytochemical Screening

Qualitative and quantitative screening of the *Calliandra portoricensis* extracts were carried out using the methods of Harborne (1973) for alkaloids, flavonoids, saponin, tannins, polyphenols and reducing compounds; Sofowora (1982) for glycosides; Trease and Evans (1983) for phlobatanins, anthraquinones and hydroxymethyl anthraquinones. 2g of the concentrated extracts were dissolved in 10ml of 0.9% saline used for each component of the qualitative and quantitative analysis.

Selective Solvent Extraction

A measured weight of the processed sample was boiled in 100ml of 2M HCL solution under reflux for 40 minutes. After cooling and filtering, the filtrate was treated with equal volume of ethyl acetate. This technique has a preferential selection for flavonoids in the ethyl acetate phase (Harborne, 1973). The total phenols (polyphenols) were extracted from 200mg of sample with 10ml concentrated methanol by the Folin-ciocatean spectrophotometer technique (AOAC, 1990) and the extract analyzed and shown to be rich in polyphenols since methanol has selective extraction capability for phenols.

Animal Treatment

A total of 30 albino wistar rats weighing between 90-120grams were used for this study. The rats were assigned into five treatment groups with group one as control with no venom challenge and extract treatment. Treatment group two was given 0.2ml of 1mg/ml of viperian venom. Groups three, four and five received the same dose of the venom. Four hours after the venom challenge, calculated dose of (0.5ml of 100mg/100g body weight) flavonoid-rich, polyphenol-rich and whole ethanolic extracts were given to the rats in groups three, four and five respectively. Both the venom and the extracts were given intramuscularly. The choice of the intramuscular route was informed by the need to follow or mimic the natural path of snake envenomation in man and animals.

Two hours after the "medication" with the plant extracts, the rats were sacrificed by euthanasia. The heart, liver and kidney samples were harvested from the various groups. These samples were blotted dry, weighted and fixed in 10% formaldehyde (pH 7.2 to 7.4) and sections of tissues were cut for histological procedures. The cut sections were then processed using the automatic tissue processor. The processed sections were stained for histological changes using standard haematoxylin-eosin (HE) routine method of Baker and Silverton (1985).

LD₅₀ of Plant Extract and Viperian Venom

The determination of the LD₅₀ of plant extract and the venom was done using the method of Lorke (1983). The LD₅₀ was determined to form a basis of dosage for subsequent assays employing sublethal doses of plant extract and venom. The LD₅₀ of *C. portoricensis* which was carried out in 2 stages (tables I and II)

clearly determined the dose of the extract at which 50% of the experimental animals died. The geometric mean of the non-lethal dose and the lowest lethal dose was calculated as the LD₅₀ (Lorke, 1983). This geometric mean gave a value of 150mg/kg body weight (b.w). The LD₅₀ of the venom was similarly determined and gave a value of 250µg/kg b.w.

Table. 1: Determination of LD₅₀ of *C. portoricensis* (Stage 1).

Substance	Doses (mg/kg b.w)	Mortality
Ethanolic extract	10,000	3/3
Ethanolic extract	625	3/3
Ethanolic extract	39	1/3

Table. 2: Determination of LD₅₀ of *C. portoricensis* (Stage 2).

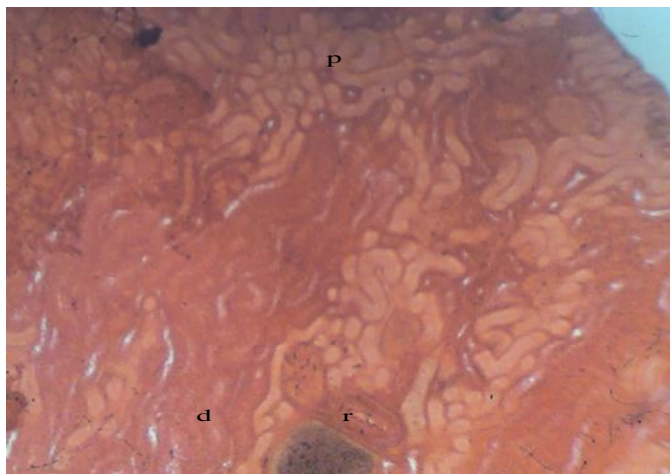
Substance	Doses (mg/kg b.w)	Mortality
Ethanolic extract	5	0/2
Ethanolic extract	39	0/2
Ethanolic extract	150	1/2

RESULTS

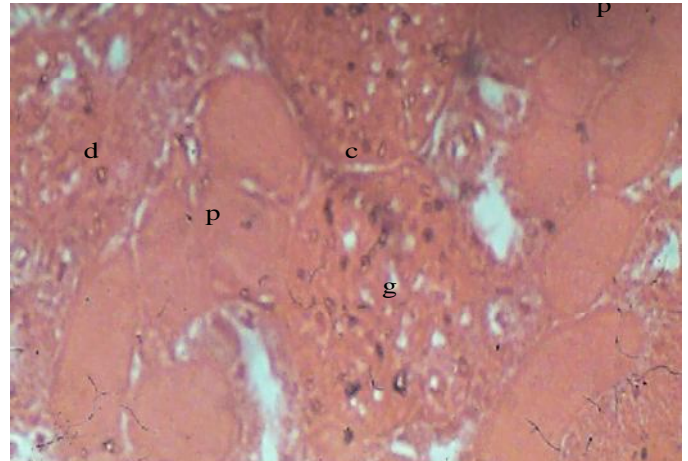
The results of the histopathological responses of the heart, liver and kidney challenged with viperian venom to extracts of *C. portoricensis* are presented in plates 1-15.

Using light microscopy (x10 and x40 magnifications), the histopathological changes especially prominent lesions and observed recoveries were photographed. Plates 1 and 2 show renal cortex and hepatic portal triad representing organs in the control group one which were normal.

In the venom-treated group two represented by V (plates 3-5), the heart portrayed a severe non-bacterial endocarditis and focal areas of myonecrosis (carditis), the kidney acute glomerulotubular necrosis (acute renal failure) and the liver acute non-bacterial hepatocellular inflammation (acute hepatitis). The histopathological changes observable in the flavonoid-rich group three represented by VF (plates 6-8) were as follows: mild non-bacterial endocarditis with myocardial edema, focal areas of renal cortical necrosis (ischaemic necrosis) and acute tubular necrosis and acute hepatocellular congestion with stasis in the liver.



Plat. 1: Kidney cortex x10. Micrograph of renal cortex showing the renal corpuscles (r), proximal (p) and distal (d) convoluted tubules.



Plat. 1b: Kidney cortex x40. Micrograph at a higher magnification shows the renal corpuscles to be made up of Glomerulus (g) encased in a capsule (c) (Bowman's Capsule) which is continuous with the wall of the proximal (p) tubule. The distal (d) tubules are in close proximity to the Glomerulus and are fewer in the section.

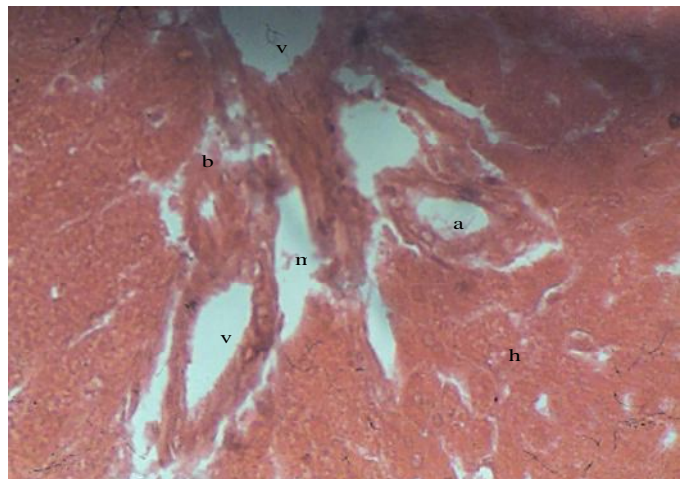
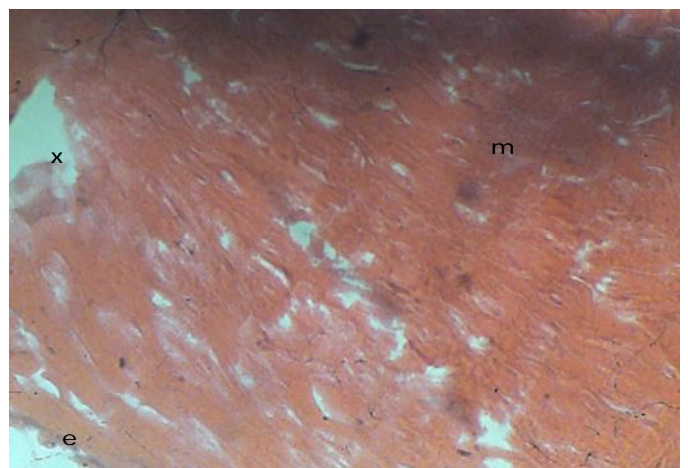
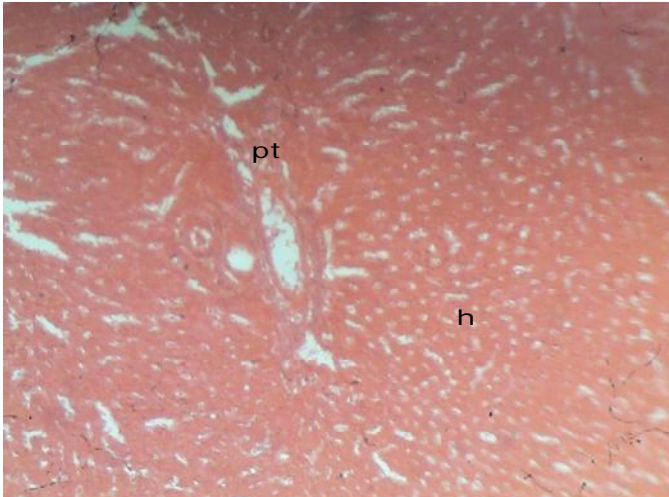


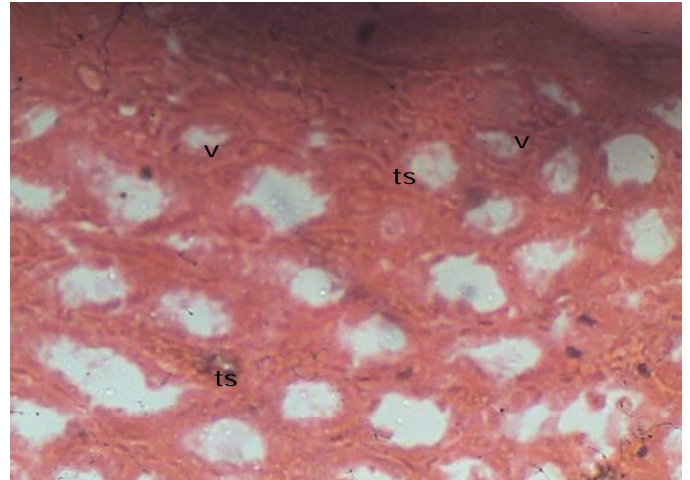
Plate. 2: Liver portal tract x 40. At higher magnification, the portal tract is seen to contain branches of the portal vein (v), hepatic artery (a) and bile duct (b), within the space of Mor (m). Hepatocytes (h) from adjacent lobes are aligned in close proximity to the vessels in the tract.



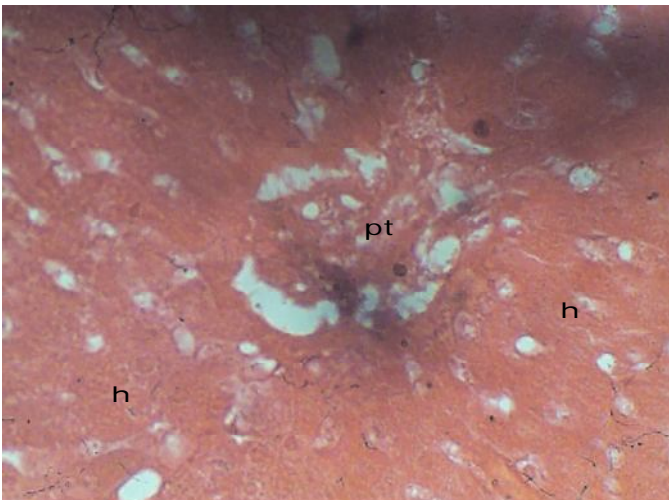
Plat. 3: V myocardium x 40. Micrograph at higher magnification shows destruction of the interdigitation and intercalations, with myonecrosis (x). Inflammatory cells are however absent.




Plat. 4: V liver portal tract x 10.
Micrograph shows the portal tract (pt) and component vessels surrounded by normal looking hepatocytes(h).



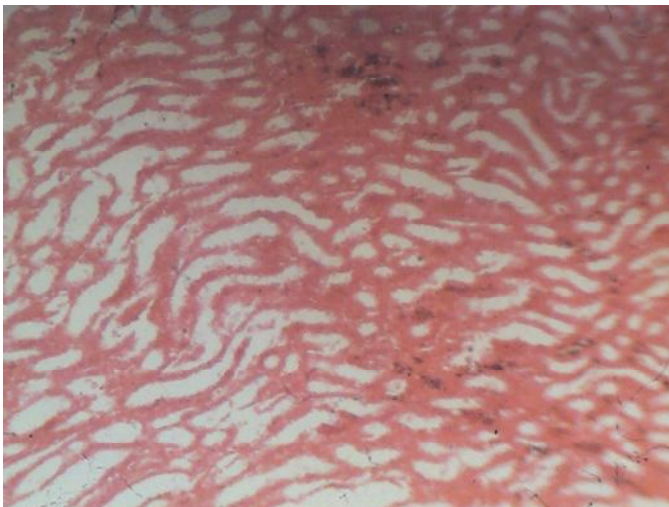
Plat. 5b: V kidney medulla x 40.
At higher magnification, there is marked tubulo-interstitial edema as well as focal necrosis of the tubule epithelial cells. Blood vessels (v) are dilated but there is no evidence of stasis nor presence of inflammatory cells.




Plat.4b: V liver portal tract x 40.
The hepatocytes (h) at higher magnification are gradually losing their cellular outline and nuclei are becoming less conspicuous. pt = portal tract.



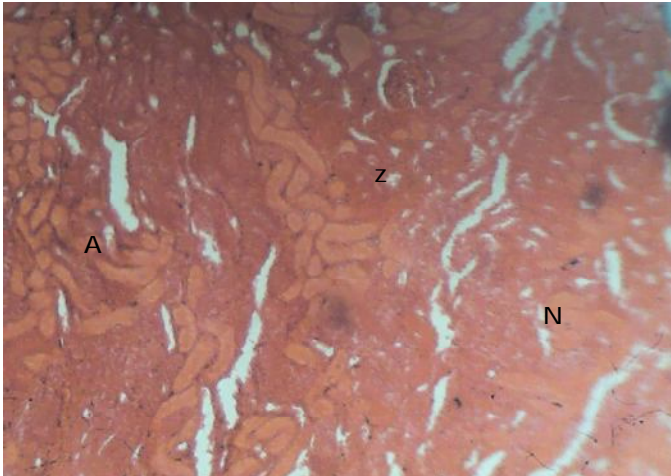
Plat. 6a: VF Endocardium x 10.
Micrograph shows mild fibrinous (f) deposits on the endocardial surface (e), diffuse perforations in the subendocardial connective tissue, and mild myocardial edema (m).



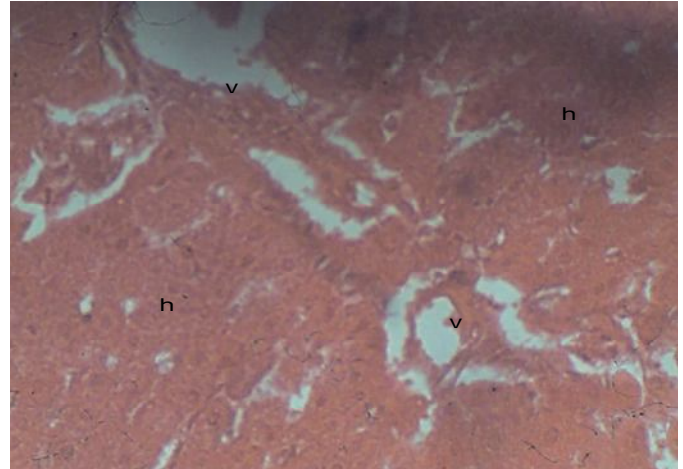
Plat. 5a: V kidney medulla x 10.
Micrograph at this magnification show swelling of the tubulo-interstitial spaces (ts) in the medulla



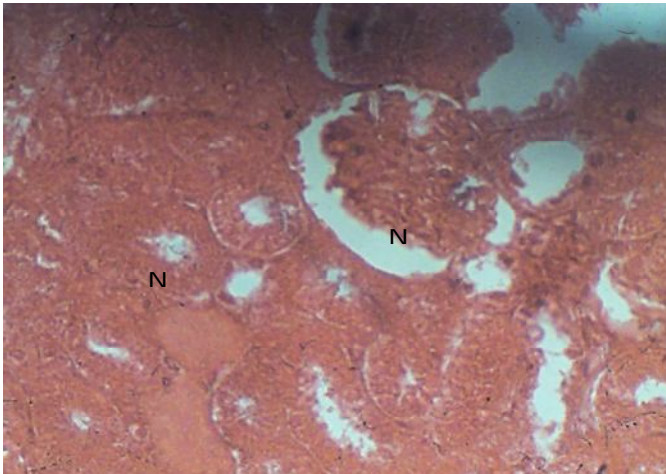
Plat. 6b: VF Endocardium x 40.
Micrograph shows mild fibrinous deposits on the endocardial surface, diffuse perforations in the subendocardial connective tissue, and mild myocardial edema (m). Myocardial cyto architecture is retained.



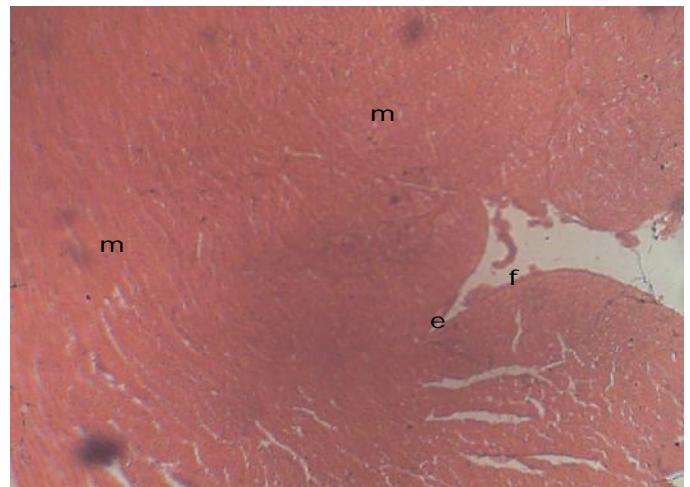Plat. 7a: VF kidney cortex x 10.
Micrograph shows areas of ischemic necrosis N (ghost cells: faint staining cells with poor cellular outline) and edematous within the renal cortex, and an adjoining hyperemic zone (z). The area marked A contains normal renal cortical tissues having distinct outline in contrast with the necrotic zone N. Inflammatory cells are however absent.



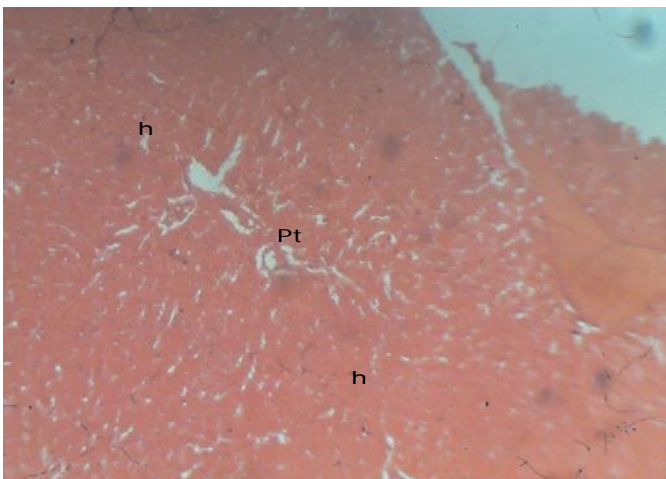
Plat. 8b: VF liver Portal tract x 40.
A higher magnification shows loss of hepato-cellular outline, hydropic degeneration and nuclei disintegration. The endothelium of the vessels in the tract are also affected. The tissue is generally edematous and poor staining. Inflammatory cells are however absent.



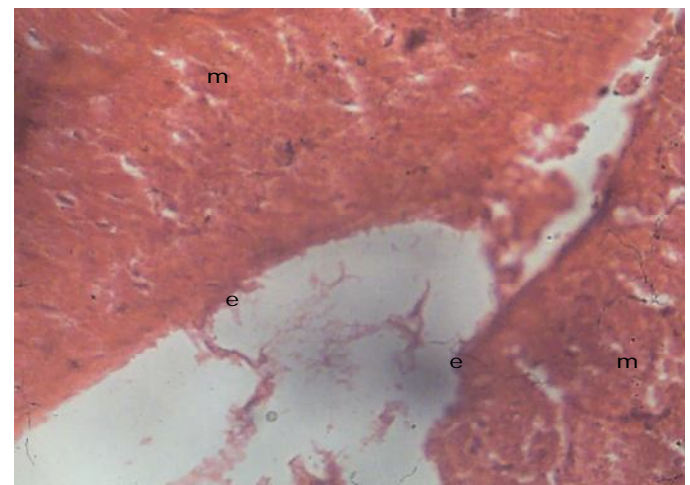
Plat. 7b: VF kidney cortex x 40.
Micrograph at a higher magnification shows diffused cellular degeneration within the necrotic area N, affecting all the renal cortical tissues. Inflammatory cell are absent.



Plat. 9a: VP Endocardium x 10.
Micrograph shows intact, smooth, thin endocardium (e) with mild fibrinous (f) deposits on its surface. The myocardium (m) looks normal.

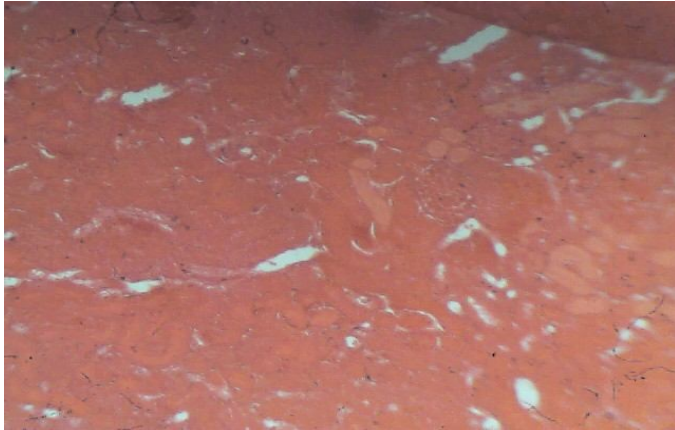


Plat. 8a: VF liver portal tract x 10.
Micrograph shows the portal tract (pt) and normal looking hepatocytes (h) surrounding it.

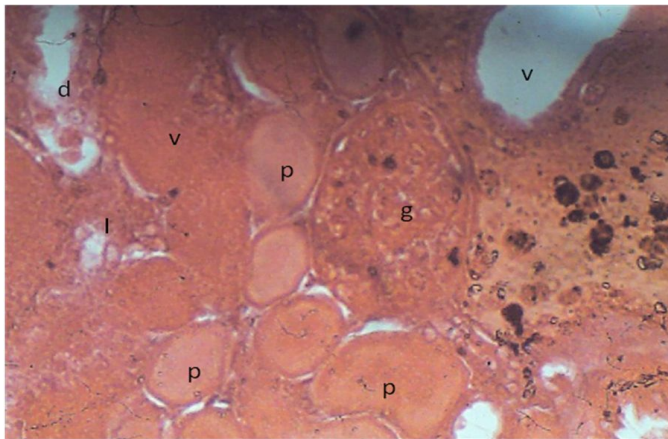


Plat. 9b: VP Endocardium x 40.
A higher magnification shows the endothelium of the endocardium (e) to be partially desquamated in some areas, and the myocardium (m) to be slightly edematous. The myocardial cyto-architecture is retained.

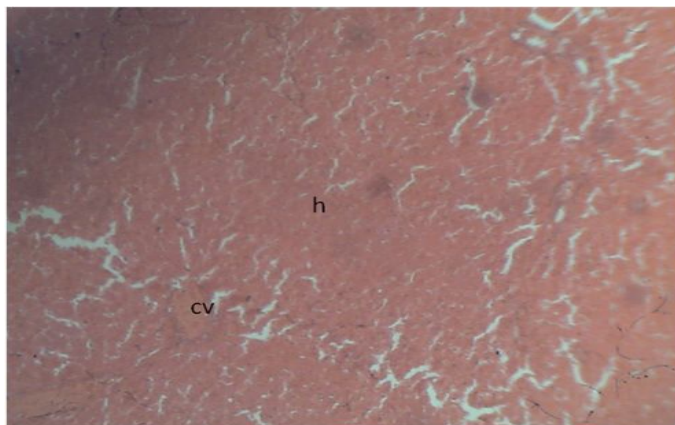
The effects of polyphenol-rich extract of group four (plates 9-11 and represented by VP) showed non-bacterial endocarditis with renal cortico-medullary congestion with focal tubular necrosis and no hepatic abnormality detectable in the liver.



Plat. 10a: VP kidney cortex x 10. Micrograph shows normal looking renal cortical tissues. g = glomerulus, p = proximal convoluted tubules, d = distal convoluted tubules.

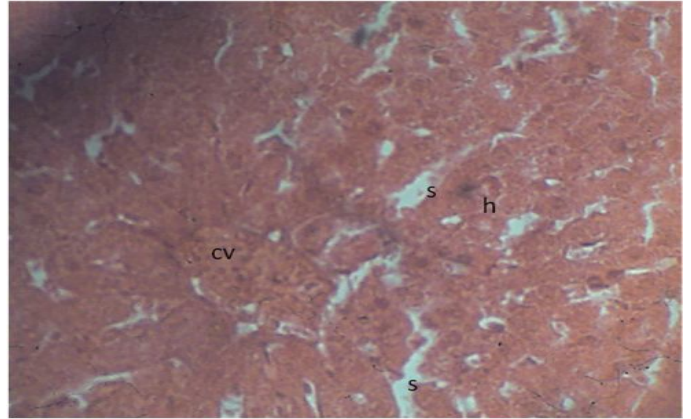


Plat. 10b: VP kidney cortex x 40. A higher magnification shows loss of brush border of proximal (p) tubular epithelial cells, distal (d) tubular epithelial necrosis. Glomerulus (g) and renal cortical vessels (v) are congested. The interstitium (I) is hyperemic and edematous. Dark particles are artefacts.

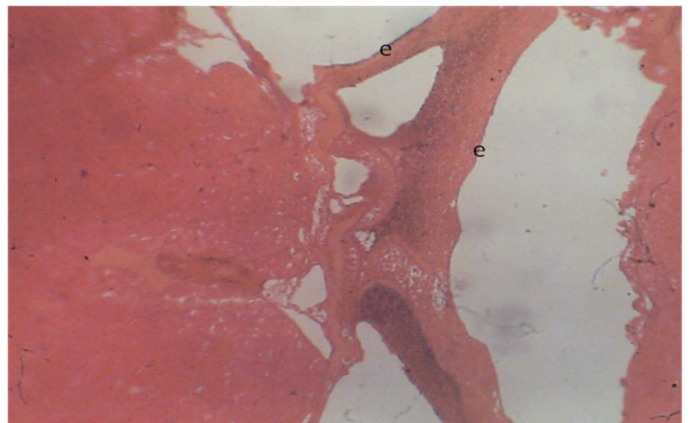


Plat. 11a: VWEE Endocardium x 10. Micrograph shows the endocardium (e) to be thickened and partially detached from the myocardium. There are perforations within the sub endocardial tissue but no fibrinous deposits seen on its surface.

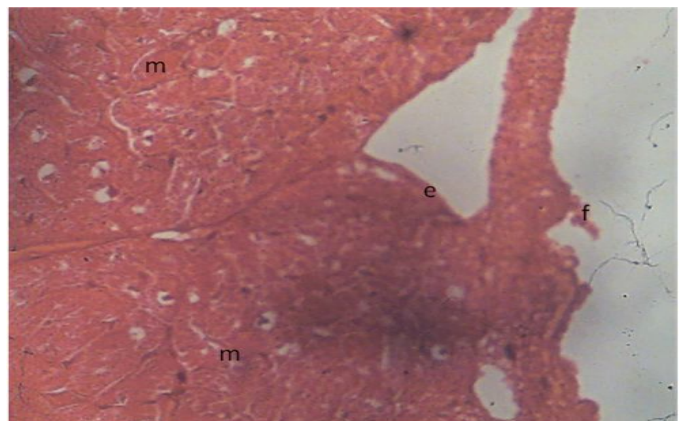
In the whole ethanolic extract group five (plates 12-15 represented by VWEE), the following changes and/or recoveries were observed histologically--the heart showed non-bacterial endocarditis, renal cortical necrosis and medullary congestion and mild peri-central hepatic congestion and edema.



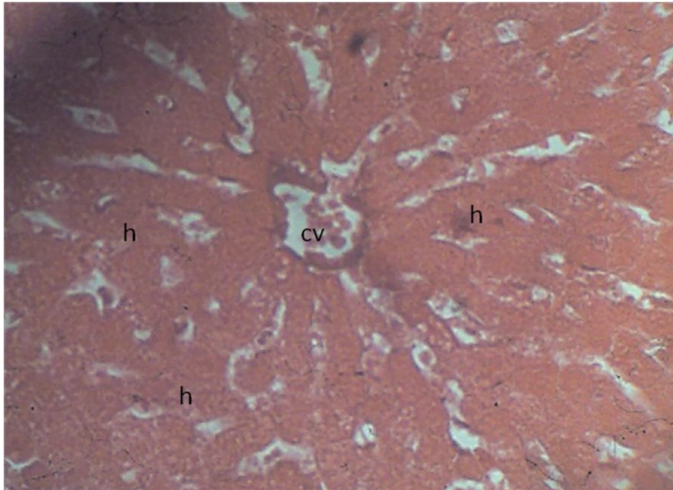
Plat. 11b: VP liver central vein x 40. Micrograph shows central venous congestion with evidence of stasis (cv). Hepatocytes (h) are poor staining though their cellular outline and nucleus are distinct. There is mild tissue edema. S = sinusoids



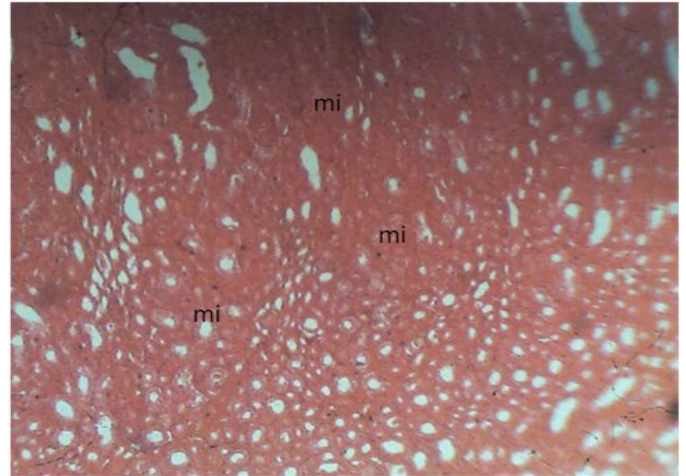
Plat. 12a: VWEE Endocardium x 10. Micrograph shows the endocardium (e) to be thickened and partially detached from the myocardium. There are perforations within the sub endocardial tissue but no fibrinous deposits seen on its surface.



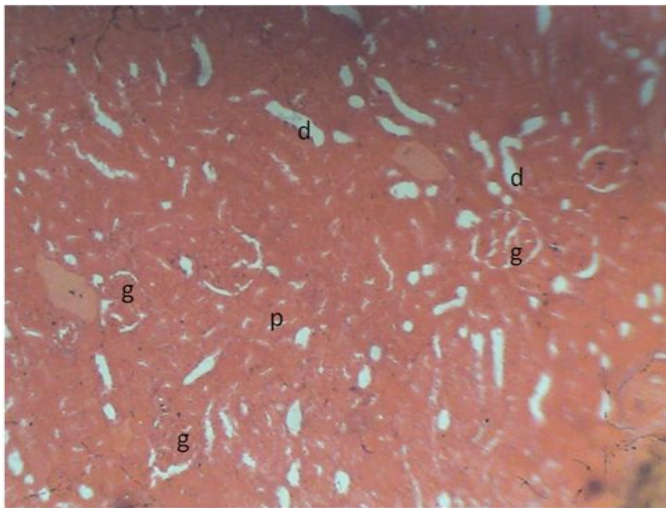
Plat. 12b: VWEE Endocardium x 40. A higher magnification shows some parts of the endocardium to be swollen with fine particles adherent to its surface. The myocardium (m) is non remarkable.



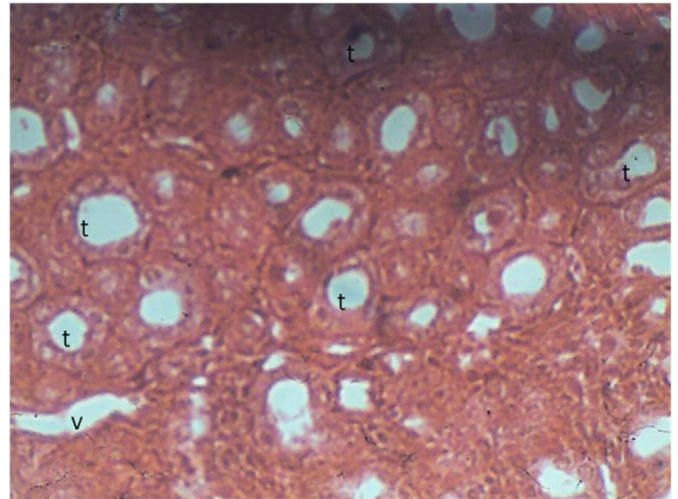
Plat. 13: VWEE liver central vein x 40.
A higher magnification shows mild reversible hydropic changes in the hepatocytes (h) and red cell stasis within the central vein (cv) and sinusoids (s).



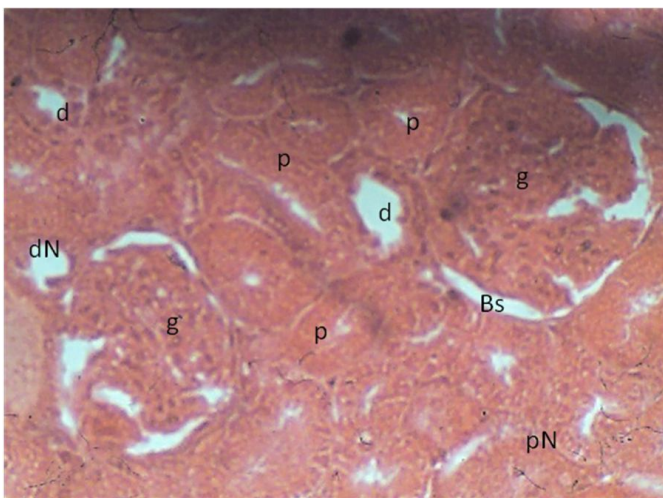
Plat. 15a: VWEE kidney medulla x 10.
Micrograph shows focal areas of thickening of the medullary interstitium.



Plat. 14a: VWEE kidney cortex x 10.
Micrograph of renal cortex showing the normal looking Glomerulus and convoluted tubules.



Plat. 15b: VWEE kidney medulla x 40.
Micrograph at a higher magnification shows the epithelium of the tubules (t) to be intact. The interstitial vessels (v) are dilated with no evidence of stasis nor inflammatory cellular infiltration.



Plat. 14b: VWEE kidney cortex x 40.
A higher magnification shows swelling of the glomerular (g) tissues with congestion within the Bowman's space (Bs), diffused areas of proximal tubular necrosis (pN) and focal areas of distal tubular epithelial necrosis (dN). P = normal proximal tubule; d = normal distal tubule.

DISCUSSION

From the histopathology, positive pathophysiological changes and/or recoveries can be said to have occurred following the use of calculated doses of *C. portoricensis* extracts in experimental rats challenged with calculated dose of viperian venom. The group treated with the extracts showed reduction in tissue injury compared to the group challenged with venom alone, though not as good as the control group. This reduction is more pronounced in the venom/polyphenol rich extract group, followed by the venom/flavonoid-rich extract and lastly the venom/whole ethanolic extract groups when the whole tissue are considered, though some of the tissues had variable effects with respect to the specific extract used. The pronounced reduction in tissue damage in the polyphenol-rich extract may be attributed to the complexation of the polyphenol-rich extract and the venom peptides (Houghton, 1993) especially with the venom phospholipase A₂ enzymes. The consequence of this complexation in this group was the observed mild cardiotoxic, mild nephrotoxic and mild hepatotoxic effects. In

the flavonoid-rich extract group, mild cardiotoxic, moderate nephrotoxic but severe hepatotoxic effects were discernable. The whole ethanolic extract group demonstrated moderate cardiotoxic, moderate nephrotoxic and mild hepatotoxic effects. From these observations, one may infer that the polyphenol-rich extract extracted more of the venom and/or modified it to a less potent state than the other extracts of *C. portoricensis*.

These findings largely reflected the observations in the enzyme assays and lipid profiles at the molecular level carried out in earlier studies.

CONCLUSION

The histopathological study revealed that there was a marked reduction in tissue injury in all the organs (heart, liver and kidney) in the groups treated with *C. portoricensis* extracts. This reduction which was more marked in the venom/polyphenol-extract group could be attributed to the complexation of polyphenolics and the venom enzymes (Houghton, 1993). So the adverse histopathological changes and damages were attenuated by these extracts in experimental rats.

REFERENCES

- Amaral C. F., da Silva, O. A., Goody, P., Miranda, D. Renal cortical necrosis following *Bothrops jararaca* and *B. jararacussu* snakebite. *Toxicon*. 1985; 23, 877 – 885.
- AOAC. Official Method of Analysis of the Association of Analytical Chemists. AOAC. Washington D. C. (1990) 223 – 225.
- Baker FJ and Silverton RE. Introduction to Medical Laboratory Technology, 6th Ed. Butterworths London (1985) 320 – 330.
- Corrigan P., Russel, FE & Waninschal J. (1978). Clinical reactions to antivenin. Toxins of animal, plant and microbials. In P. Rosenberg (Ed.) (pp. 457 – 465) New York: Oxford, Pergamon press.
- Harborne JB. Phytochemical Methods. A guide to modern technique of plant analysis. Chapman and Hall, London (1973) 188 -190.
- Houghton P. J. In vitro testing of some West African and Indian plants used to treat snakebites. *Medicament et Nutrition: L' Approche ethnopharmacologique*. 1993; 263 – 274.
- Lorke, D. (1983). A new approach to practical Acute Toxicity Test. Institute Fur Toxicologie, Bayer A. G, Friedrich – Ebert- Strasse. 217, D- 5600 Wuppertal, Federal Republic of Germany.
- Sofowora EA. Medicinal Plants and Traditional Medicine in Africa. John Wiley and Sons, New York (1982) 43 - 46.
- Sutherland S. K. Serum reactions analysis of commercial anti-venom and possible role of anti-complementary activity in de novo reactions to anti-venom and antitoxins *Med. J. Aust.*, 1977; 1, 613 – 615.
- Swaroop S. Grab B. Snakebite mortality in the World. *Bull WHO*. 1954; 61, 949 – 956.
- Trease GE and Evans EC. *Pharmacology* 12th ed. Bailliere Tindall, London (1983)